

ARCHIVIO ITALIANO DI UROLOGIA E ANDROLOGIA

ARCH IT UROL ANDROL

ARCHIVES OF ITALIAN UROLOGY AND ANDROLOGY

Vol. 82; n. 3, September 2010

Indexed in: Medline/Index Medicus, EMBASE/Excerpta Medica, Medbase/Current Opinion, SIIC Data Base, SCOPUS

**Paediatric urolithiasis in central coast region of Tunisia:
Changes in stone composition according to age and gender.**

Akram Alaya, Abdellatif Nouri, Mohamed Fadhel Najjar

**Calcium oxalate nephrolithiasis:
Urinary "medium size peptides" analysis using MALDI-TOF mass spectrometry.**

Alessandro D'Addessi, Luca Bongiovanni, Matteo Vittori, Chiara Fanali,
Nazario Foschi, Massimo Castagnola, Pier Francesco Bassi

Urinary alkalization for the treatment of uric acid nephrolithiasis.

Elisa Cicerello, Franco Merlo, Luigi Maccatrozzo

**30 minutes high energy transurethral microwave thermotherapy (30 minutes TUMT)
for the treatment of chronic urinary retention in patients with ASA II-III-IV.**

Mauro Dicuio, Stepan Vesely, Tomas Knutson, Jan-Erik Damber,
Diego Ettore Cuzzocrea, Christer Dahlstrand

**Can Sonovue® targeted biopsy replace extended or saturation biopsy
in prostate cancer diagnosis? Our experience at primary and repeat biopsy.**

Pietro Pepe, Giuseppe Candiano, Michele Pennisi, Francesco Aragona

Elasto-sonography of the testis: Preliminary experience.

Marco Grasso, Salvatore Blanco, Marco Raber, Luca Nespoli

Corporoplasty by plication: Out patient surgery for the correction of penile curvature.

Mauro Seveso, Gianluigi Taverna, Guido Giusti, Alessio Benetti, Orazio Maugeri,
Alessandro Piccinelli, Pierpaolo Graziotti

Effect of aging on urinary incontinence in woman.

Carlo Vecchioli-Scaldazza, Carolina Morosetti

**Risk of prostate cancer at first saturation re-biopsy in a patient
with previous diagnosis of HGPIN.**

Roberto Giulianelli, Stefano Brunori, Barbara Cristina Gentile, Giorgio Vincenti, Stefano Nardoni,
Teuta Shestani, Luca Mavilla, Luca Albanesi, Francesco Attisani, Francesco Pisanti

Laparoscopic heminephrectomy in horseshoe kidney: A case report.

Dario Del Biondo, Antonio Celia, Guglielmo Zeccolini, Guglielmo Breda

Fibrous pseudotumor originating from tunica albuginea testis: A case report.

Yusuf Ozlem Ilbey, Emin Ozbek, Emre Can Polat, Abdulmuttalip Şimşek, Adnan Somay

**Management of large prostatic abscess associated with
urethral stenosis and penile cancer recurrence.**

Andrea Benedetto Galosi, Gianni Parri, Vito Lacetera, Giovanni Muzzonigro

Chylous ascites following laparoscopic adrenalectomy: Case report and literature review.

Galanakis Joanny, Antonio Celia, Guglielmo Zeccolini, Dario Del Biondo, Guglielmo Breda

Kidney hibernoma: Case report and literature review.

Alessandro Delsignore, Stefania Ranzoni, Matteo Arancio, Carlo Marchetti,
Giuseppe Landi, Alessandro Mina, Maurizio Marcato, Carlo Martinengo

Primary obstructive megaureter in adults: Management strategy in a young woman.

Andrea Solinas, Antoncarlo Pau, Mohammed Ayyoub, Mauro Frongia

**Official Journal
of the SIEUN**

S.I.E.U.N.

Società
Italiana di
Ecografia
Urologica
Nefrologica e
andrologica

**Official Journal
of the SIUrO**

SIUrO
Società Italiana di
Urologia Oncologica

**Official Journal
of the UrOP**

UrOP
Urologi
Ospedalità
Gestione Privata

**SCRIPTA
MANENT
EDIZIONI**

ARCHIVIO ITALIANO DI UROLOGIA E ANDROLOGIA

ARCH IT UROL ANDROL

ARCHIVES OF ITALIAN UROLOGY AND ANDROLOGY

Official Journal of the SIEUN, the SIUrO, the UrOP

EDITORS

M. Maffezzini (Genova), G. Perletti (Busto A.), A. Trinchieri (Lecco)

EDITORIAL BOARD

P. F. Bassi (Roma), A. Bossi (Villejuif - France), P. Caione (Roma), F. Campodonico (Genova), L. Carmignani (Milano), L. Cheng (Indianapolis - USA), L. Cindolo (Avellino), G. Colpi (Milano), G. Corona (Firenze), A. Giannantoni (Perugia), P. Gontero (Torino), S. Joniau (Leuven - Belgio), F. Keeley (Bristol - UK), L. Klotz (Toronto - Canada), M. Lazzeri (Firenze), B. Ljungberg (Umeå - Svezia), A. Minervini (Firenze), N. Mondaini (Firenze), G. Muir (London - UK), G. Muto (Torino), R. Naspro (Bergamo), A. Patel (London - UK), G. Preminger (Durham - USA), D. Ralph (London - UK), A. Rodgers (Cape Town - South Africa), F. Sampaio (Rio de Janeiro - Brazil), K. Sarica (Istanbul - Turkey), L. Schips (Vasto), H. Schwaibold (Bristol - UK), A. Simonato (Genova), S. Siracusano (Trieste), C. Terrone (Novara), A. Timoney (Bristol - UK), A. Tubaro (Roma), R. Zigeuner (Graz - Austria)

SIUrO EDITOR

G. Martorana (Bologna)

SIUrO ASSISTANT EDITOR

A. Bertaccini (Bologna)

SIUrO EDITORIAL BOARD

V. Altieri (Napoli), M. Battaglia (Bari), F. Boccardo (Genova), E. Bollito (Torino), S. Bracarda (Perugia), G. Conti (Como), J.G. Delinassios (Athens - Greece), A. Lapini (Firenze), N. Longo (Napoli), V. Scattoni (Milano), G. Sica (Roma), C. Sternberg (Roma), R. Valdagni (Milano)

SIEUN EDITOR

P. Martino (Bari)

SIEUN EDITORIAL BOARD

E. Belgrano (Trieste), F. Micali (Roma), M. Porena (Perugia), F.P. Selvaggi (Bari), C. Trombetta (Trieste), G. Vespasiani (Roma), G. Virgili (Roma)

UrOP EDITOR

C. Boccafoschi (Alessandria)

UrOP EDITORIAL BOARD

M. Coscione (Benevento), G. Fiaccavento (San Donà di Piave - VE), F. Galasso (Avellino), M. Lazzeri (Firenze), F. Narcisi (Teramo), C. Ranno (Catania), V. Pansadoro (Roma), M. Schettini (Roma)

ASSOCIAZIONE UROLOGI LOMBARDI EDITOR

F. Rocco (Milano)

HONORARY EDITOR

E. Pisani (Milano)

Indexed in: Medline/Index Medicus - EMBASE/Excerpta Medica - Medbase/Current Opinion - SIIC Data Base
www.architurol.it



Contents

Paediatric urolithiasis in central coast region of Tunisia: Changes in stone composition according to age and gender.	<i>Pag. 135</i>
Akram Alaya, Abdellatif Nouri, Mohamed Fadhel Najjar	
Calcium oxalate nephrolithiasis: Urinary "medium size peptides" analysis using MALDI-TOF mass spectrometry.	<i>Pag. 140</i>
Alessandro D'Addessi, Luca Bongiovanni, Matteo Vittori, Chiara Fanali, Nazario Foschi, Massimo Castagnola, Pier Francesco Bassi	
Urinary alkalization for the treatment of uric acid nephrolithiasis.	<i>Pag. 145</i>
Elisa Cicerello, Franco Merlo, Luigi Maccatrozzo	
30 minutes high energy transurethral microwave thermotherapy (30 minutes TUMT) for the treatment of chronic urinary retention in patients with ASA II-III-IV.	<i>Pag. 149</i>
Mauro Dicuio, Stepan Vesely, Tomas Knutson, Jan-Erik Damber, Diego Ettore Cuzzocrea, Christer Dahlstrand	
Can Sonovue® targeted biopsy replace extended or saturation biopsy in prostate cancer diagnosis? Our experience at primary and repeat biopsy.	<i>Pag. 155</i>
Pietro Pepe, Giuseppe Candiano, Michele Pennisi, Francesco Aragona	
Elasto-sonography of the testis: Preliminary experience.	<i>Pag. 160</i>
Marco Grasso, Salvatore Blanco, Marco Raber, Luca Nespoli	
Corporoplasty by plication: Out patient surgery for the correction of penile curvature.	<i>Pag. 164</i>
Mauro Seveso, Gianluigi Taverna, Guido Giusti, Alessio Benetti, Orazio Maugeri, Alessandro Piccinelli, Pierpaolo Graziotti	
Effect of aging on urinary incontinence in woman.	<i>Pag. 167</i>
Carlo Vecchioli-Scaldazza, Carolina Morosetti	
Risk of prostate cancer at first saturation re-biopsy in a patient with previous diagnosis of HGPIN.	<i>Pag. 172</i>
Roberto Giulianelli, Stefano Brunori, Barbara Cristina Gentile, Giorgio Vincenti, Stefano Nardoni, Teuta Shestani, Luca Mavilla, Luca Albanesi, Francesco Attisani, Francesco Pisanti	
Laparoscopic heminephrectomy in horseshoe kidney: A case report.	<i>Pag. 175</i>
Dario Del Biondo, Antonio Celia, Guglielmo Zeccolini, Guglielmo Breda	
Fibrous pseudotumor originating from tunica albuginea testis: A case report.	<i>Pag. 178</i>
Yusuf Özlem Ilbey, Emin Özbek, Emre Can Polat, Abdulmuttalip Şimşek, Adnan Somay	
Management of large prostatic abscess associated with urethral stenosis and penile cancer recurrence.	<i>Pag. 181</i>
Andrea Benedetto Galosi, Gianni Parri, Vito Lacetera, Giovanni Muzzonigro	
Chylous ascites following laparoscopic adrenalectomy: Case report and literature review.	<i>Pag. 186</i>
Galanakis Joanny, Antonio Celia, Guglielmo Zeccolini, Dario Del Biondo, Guglielmo Breda	
Kidney hibernoma: Case report and literature review.	<i>Pag. 189</i>
Alessandro Delsignore, Stefania Ranzoni, Matteo Arancio, Carlo Marchetti, Giuseppe Landi, Alessandro Mina, Maurizio Marcato, Carlo Martinengo	
Primary obstructive megaureter in adults: Management strategy in a young woman.	<i>Pag. 192</i>
Andrea Solinas, Antoncarlo Pau, Mohammed Ayyoub, Mauro Frongia	

ERRATA CORRIGE

The names of the Authors of the paper "Extracorporeal shock wave therapy in the treatment of Peyronie's disease: Long term results" published in *Archivio Italiano di Urologia e Andrologia* vol. 82 n. 2, June 2010 are as follows: Ettore De Berardinis, Gian Maria Busetto, Gabriele Antonini, Riccardo Giovannone, Vincenzo Gentile.

GENERAL INFORMATION

AIMS AND SCOPE

"Archivio Italiano di Urologia e Andrologia" publishes papers dealing with the urological, nephrological and andrological sciences.

Original articles on both clinical and research fields, reviews, editorials, case reports, abstracts from papers published elsewhere, book reviews, congress proceedings can be published.

Papers submitted for publication and all other editorial correspondence should be addressed to:

Edizioni Scripta Manent s.n.c.

Via Bassini 41

20133 Milano - Italy

Tel. +39 0270608091 - Fax +39 0270606917

e-mail: scriman@tin.it - architurolog@gmail.com

web: www.architurolog.it

COPYRIGHT

Papers are accepted for publication with the understanding that no substantial part has been, or will be published elsewhere.

By submitting a manuscript, the authors agree that the copyright is transferred to the publisher if and when the article is accepted for publication.

The copyright covers the exclusive rights to reproduce and distribute the article, including reprints, photographic reproduction and translation.

No part of this publication may be reproduced, stored in a retrieval system, or transmitted in any form or by any means, electronic, mechanical, photocopying, recording or otherwise, without the prior written permission of the Publisher.

Registrazione: Tribunale di Milano n.289 del 21/05/2001

Direttore Responsabile: Pietro Cazzola

Direzione Generale: Armando Mazzù

Direzione Marketing: Antonio Di Maio

Consulenza grafica: Piero Merlini

Impaginazione: Stefania Cacciaglia

Stampa:

Arti Grafiche Bazzi, Milano

BUSINESS INFORMATION

SUBSCRIPTION DETAILS

Annual subscription rate

(4 issues) is Euro 52 for Italy

and US \$130 for all other Countries.

Price for single issue: Euro 13 for Italy

US \$32,5 for all other Countries.

Issues will be sent by surface mail;

single issues can also be sent by air mail at an extra charge of US \$12.

Subscription orders should be sent to:

Edizioni Scripta Manent s.n.c.

Via Bassini 41

20133 Milano - Italy

Tel. +39 0270608091 - Fax +39 0270606917

e-mail: scriman@tin.it / architurolog@gmail.com

www.architurolog.it

Payments should be made by bank cheque to:

Edizioni Scripta Manent s.n.c.

For Italy: conto corrente postale n. 20350682

intestato a Edizioni Scripta Manent s.n.c.

Claim for missing issues should be made within 3 months from publication for domestic addresses, otherwise they cannot be honoured free of charge.

Changes of address should be notified Edizioni Scripta Manent s.n.c. at least 6-8 weeks in advance, including both old and new addresses.

The handling of personal data concerning subscribers is managed by our electronic data base.

It is in accordance with the law 675/96 regarding the tutorship of personal data.

The use of data, for which we guarantee full confidentiality, is to keep our readers up to date with new initiatives, offers and publications concerning Edizioni Scripta Manent s.n.c.

Data will not be released or disseminated to others and the subscriber will be able to request, at any time, variation or cancellation of data.

ADVERTISING

For details on media opportunities within this journal please contact

Mr. Armando Mazzù or **Mr. Antonio Di Maio**
at +39 0270608060.

Paediatric urolithiasis in central coast region of Tunisia: Changes in stone composition according to age and gender.

Akram Alaya¹, Abdellatif Nouri², Mohamed Fadhel Najjar¹

¹ University Hospital, Department of Biochemistry and Toxicology, 5000 Monastir, Tunisia;

² University Hospital, Department of Pediatric Surgery, 5000 Monastir, Tunisia

Summary

Objective: Studies evaluating the influence of age and gender on the distribution of the various types of paediatric urinary calculi are scarce. Aim of our study was to highlight the modification of epidemiological characteristics of this pathology depending on patients' age and gender.

Patients and methods We present the results of a study based on 205 calculi (from 122 boys and 83 girls) analyzed by infrared spectroscopy between 1993 and 2007. 54.6% of the patients were under 5 years.

Results: Calcium oxalate (CaOx) was the predominant constituent in 54.7% of stones, followed by calcium phosphate and ammonium urate (14.6% each). We found a male preponderance for struvite stones (12.3% vs 1.2%), and an increasing prevalence of calcium oxalate stones with age (42.9% in infants vs 59.3% in older children). Purines stones were observed in 20% of cases, but their prevalence decreases with age (28.6% in infants vs 18.5% in old children).

Conclusion: the increase of calcium oxalate stone rate in school age children and the decrease of purines stones confirm the change on the etiology of urolithiasis according to age.

KEY WORDS: Urolithiasis; Age; Sex; Children; Stones; Composition; Tunisia.

Submitted 30 November 2008; Accepted 15 January 2009

INTRODUCTION

Urolithiasis in the pediatric age group occurs less frequently than in adults, with male prevalence (1-4). Epidemiological data suggest that stone composition and location change according to age (5-7). These changes are usually an expression of nutritional disorder or metabolic changes associated with aging cell (8). During our work we will try to highlight the modification of epidemiological characteristics of pediatric urolithiasis (composition and location) depending on patients' age.

PATIENTS AND METHODS

Two hundred and five children (122 boys and 83 girls) aged 3 months to 16 years with urolithiasis were admitted between 1993 and 2007 to the paediatric surgery department at the University hospital of Monastir.

Documentation included recording of age, sex, residency, age of onset of symptoms, age of diagnosis of stone disease, clinical presentation, past medical and surgical history, family history of stone disease, and recurrence

(which was considered to be present if the patient had previous surgery or spontaneous passage of stone before presentation).

Urine culture was carried out in 168 cases. All stones were documented radiologically by ultrasound and intravenous urography.

All stones were examined by infrared spectroscopy at the Laboratory (Figure 1) The structure of each one was established using stereomicroscope to define the morphology of the stone and to select its parts (nucleus or core, internal section, and external surface), in order to determine its molecular and crystalline composition by infrared spectroscopy. The stone component was considered as main component if it exceeded 70% of the total stone composition.

RESULTS

Of the 205 children with urolithiasis, 122 (59.5%) were males and 83 (40.5%) were females, sex-ratio was 1.47.

Children's age at presentation ranged from 3 months to 16 years and 55.1% of the study group was below 5 years of age. The number of patients stratified by age and sex is shown in Figure 2. Patients were predominantly coming from rural areas (66.7%) of the central coast of Tunisia.

The dietary survey showed a diet rich in sorghum and chocolate in 50.3% of patients over 10 years. The X-ray examination carried out to all our patients, demonstrated the presence of obstructive stones in 60 cases (29.2%). Multiple stones were detected in 117 patients (57%). In 140 patients (68.3%), calculi were located in the upper urinary tract (in 105 in the kidney and in 35 in the ureter), in 63 patients in the bladder, and in 2 in the urethra. Infants were more affected by bladder stone (Figure 3). No clear male predominance was observed in children with bladder (sex ratio 1.42) or kidney calculi (sex ratio 1.38), whereas male predominance was more evident in younger children under 5 years of age, and especially in those presenting with bladder calculi (sex ratio 2). Anatomical defects were detected in 16 patients (7.8%).

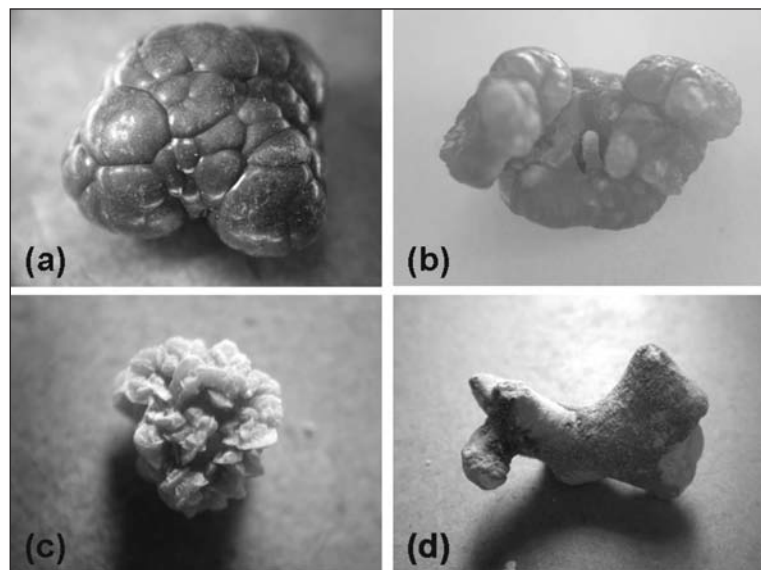
As shown in Table 1, the most common components of the urinary stones were whewellite (72.7%), ammonium urate (47.3%), and struvite in 32 (10.7%) whereas the more common component of stone nucleus was whewellite.

Young boys were more affected by struvite stones than girls ($p < 0.05$) (Table 2). The proportion of calcium oxalate and calcium phosphate stones increased with age, respectively; from 48.6%-5.7% in patients ≤ 2 years to 59.3%-14.8% in patients in the 10-16 year group (Figure 4).

DISCUSSION

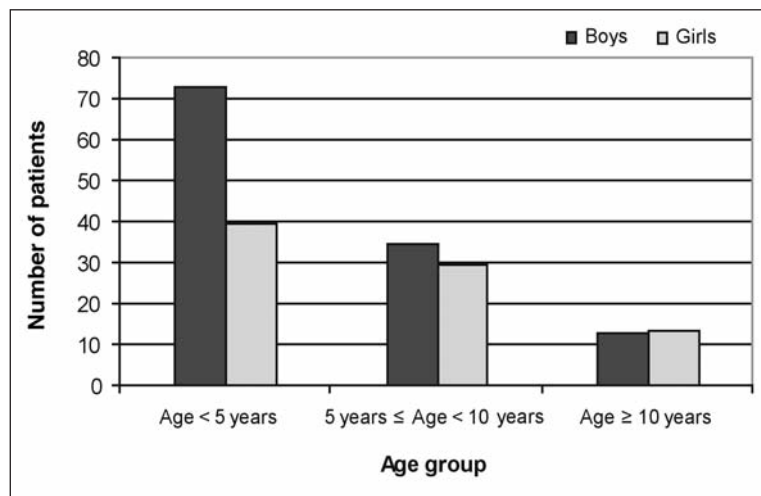
Calcium oxalate is the most frequent chemical compound of urinary calculi being present in approximately 70-80% of stones (8). According to *Daudon et al.* (9) calcium oxalate stones from developing countries are mainly observed in North Africa and Minor Asia. In our study calcium oxalate stones were found in 54.7% of all cases. This rate compare with those reported by Moroccan (10), Algerian (11) and French (12) papers. Calcium oxalate monohydrate remains the most frequent component in Tunisian children stones (13-15) even if its frequency fell during the last 12 years period (15). The absence of whewellite type Ic, excludes primary hyperoxaluria origin of whewellite stones. These data confirm those obtained from dietary survey and demonstrate the influence of dietary habit. Stone composition is very different depending on the patient's age. This difference persists throughout life (6, 16). Calcium oxalate stone linked to dietary habits, is frequent among adults more

Figure 1.
Some stones morphology.



- (a, b) Whewellite type Ia. Stone with smooth and mammillary surface.
(b) Note the presence of a papillary umbilication.
(c) Weddellite type IIb, speculated surface with thick, entangled and opaque bipyramidal crystals.
(d) Staghorn stone struvite type IVb.

Figure 2.
Age and sex distribution of 205 Tunisian children with urolithiasis.



than children (12, 17). On the contrary urinary lithiasis caused by genetic diseases is proportionately more frequent (18). This is not surprising since these diseases are congenital and can therefore occur at birth.

Struvite remains the best marker of urinary tract infections by urease producing bacteria (5, 19), particularly in young boys. Struvite was identified as the main component in 16 calculi (7.8%), thus suggesting that urea-splitting bacteria played a major part in the formation of these stones.

Table 1 shows 22 calculi containing some struvite, but in six of them the nucleus did not contain struvite, suggesting that another cause was responsible for the initial

Figure 3.
Stone location according to age.

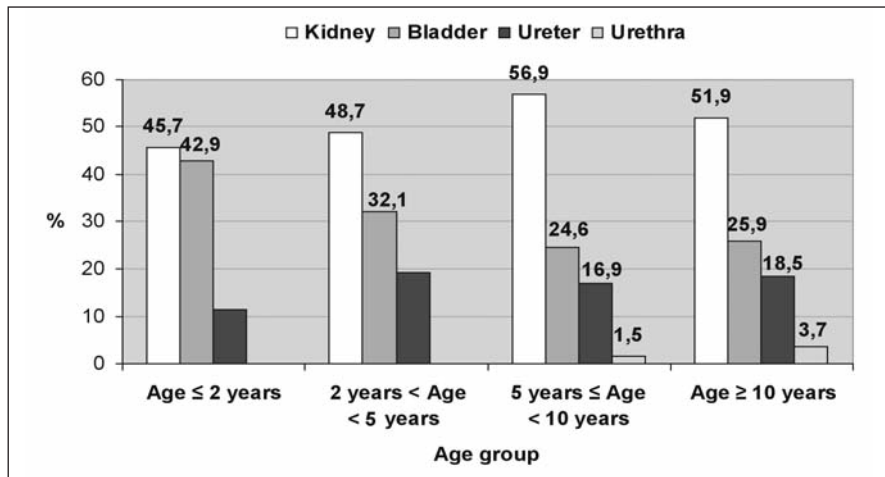


Figure 4.
Stone location according to age.

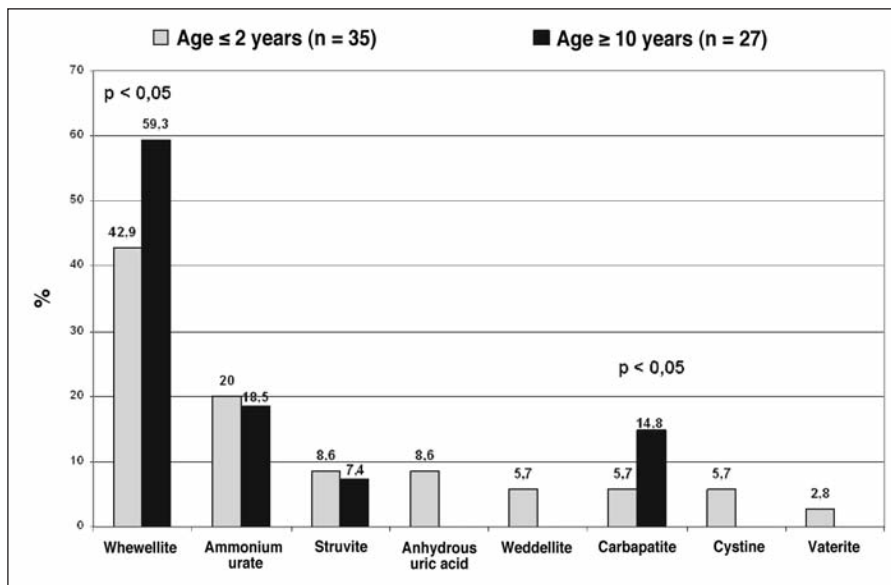


Table 1.
Stones composition according to sex (n = 205).

Component	Boys (n = 122)		Girls (n = 83)		p	Total (n = 205)	
	Number	%	Number	%		Number	%
Whewellite	79	65.8	70	82.4	p < 0.01	149	72.7
Ammonium urate	54	45.0	43	50.6	NS	97	47.3
Weddellite	37	30.8	24	28.2	NS	61	29.7
Carapatite	29	24.2	27	31.8	NS	56	27
Struvite	20	16.7	2	2.4	p < 0.001	22	10.7
Anhydrous uric acid	10	8.3	6	7.1	NS	16	7.8
Sodium urate	5	4.2	3	3.5	NS	8	3.9
PACC	1	0.8	2	2.4	NS	3	1.4
Dihydrated uric acid	2	1.7	0	0.0	-	2	1
Cystine	3	2.5	0	0.0	NS	3	1.4
Vaterite	2	1.7	0	0.0	-	2	1
Artefact	1	0,8	0	0.0	NS	1	0.5

stone process and that infection was secondary.

These results are comparable to those reported by Daudon (12) where a frequency of 9.9% was presented, but significantly less than those reported in our neighbouring countries (11, 20) and in some developed countries like Switzerland (21) where struvite accounted for 35% of cases.

The relationship between frequency of main types of stones and patients age was previously reported by Daudon *et al.* (22). This reflects both nutritional change and metabolism evolution depending on patient's age. These data were widely noted in adults (22, 23). When comparing data collected in our series between infants and older children, we found that calcium oxalate holds an absolute majority among children over 10 years ($p < 0.05$). The high frequency of the whewellite at teenage child evokes the role of hyperoxaluria food-borne in developing these stones. Indeed, the dietary survey revealed an excessive intake of chocolate and sorghum in more than half of patients in this age group. The progressive increase of calcium phosphate stones among older children is related to the concurrent decrease of calcium oxalate dihydrate (weddellite) which disappears.

Table 2.
Main component of urinary stones according to sex and age.

	Boys (n = 122)						Girls (n = 83)						Total (n = 205)	
	Age ≤ 5 years		Age > 5 years		Total		Age < 5 years		Age > 5 years		Total			
	(n = 73)		(n = 49)				(n = 39)		(n = 44)					
	Number	%	Number	%	Number	%	Number	%	Number	%	Number	%	Number	%
Calcium oxalate	45.2		59.2		50.8		58.5		59.1		60.2		54.7	
Weddellite	4	5.5	2	4.1	6	4.9	6	14.6	0	0	6	7.2	12	5.9
Whewellite	29	39.7	27	55.1	56	45.9	18	43.9	26	59.1	44	53.0	100	48.8
Calcium phosphates	13.7		16.3		14.8		9.8		18.2		14.5		14.6	
Carbapatite	10	13.7	8	16.3	18	14.8	4	9.8	8	18.2	12	14.5	30	14.6
PACC	0	0	0	0	0	0	0	0	0	0	0	0	0	0
Struvite	13.7a		10.2		12.3b		2.4a		0		1.2b		7.8	
Struvite	10	13.7	5	10.2	15	12.3	1	2.4	0	0	1	1.2	16	7.8
Purines	21.9		14.3		18.9		19.5		22.8		21.2		20	
Ammonium urate	9	12.3	5	10.2	14	11.5	7	17.1	9	20.5	16	19.3	30	14.6
Anhydrous uric acid	7	9.6	2	4.1	9	7.4	1	2.4	1	2.3	2	2.4	11	5.4
Cystine	3	4.1	0	0	3	2.5	0	0.0	0	0	0	0.0	3	1.5
Vaterite	1	1.4	0	0	1	0.8	1	2.4	0	0	1	1.2	2	1
Artifact	0	0	0	0	0	0	1	2.4	0	0	1	1.2	1	0.5

a: difference between boys and girls (age ≤ 5 years): $p < 0.05$. b: difference between boys and girls: $p < 0.05$

Ammonium urate was the main component of the nucleus in only 19.0% of our stones whereas a frequency of 29.5% was noted in our neighbouring countries (11) and a even higher frequency of 40% in Pakistan (24) in comparison to a 11% frequency reported in France (25).

According to our results, purines stones were more frequent in infants (28.6%) than in teenagers (18.5%). The most remarkable change in purines stones was the disappearance of uric acid anhydrous. Metabolic (genetic or acquired) disorder can be mentioned to explain this change. However, we believe that tubular immaturity in infants associated to a lack of reabsorption of uric acid is the main reason in this case (20).

Girls and boys under 5 years seem to be more affected than teenagers by infectious stones. At school age, incidence of infectious calculi decreases gradually in both sexes and stone composition begins to move towards more typical species represented by calcium oxalate. Our results confirm those reported in some papers (14, 15, 24, 25) which assess that younger boys are more affected by urinary tract infections.

CONCLUSION

The epidemiology of renal stones is still changing in our country towards a predominance of calcium oxalate stones. The increase of calcium oxalate stones in school age children and the decrease of struvite and purines stones confirm the change on the etiology of urolithiasis according to age.

REFERENCES

1. Basaklar AC, Kale N. Experience with childhood urolithiasis. Report of 196 cases. *Br J Urol* 1991; 67:203-5.

2. Gearhart JP, Herzberg GZ, Jeffs RD. Childhood urolithiasis: experiences and advances. *Pediatrics* 1991; 87:445-450.

3. Milliner DS, Murphy ME. Urolithiasis in pediatric patients. *Mayo Clin Proc* 1993; 68:241-8.

4. Leumann E, Hoppe B. Urolithiasis in childhood. In: Proesmans W, editor. *Therapeutic strategies in children with renal diseases*. Baillieres Clin Paediatr; 1997; 655-674.

5. Jungers P, Daudon M, Conort P. *Lithiase rénale, diagnostic et traitement*. Paris: Flammarion Médecine-Sciences 1999.

6. Daudon M, Doré B. Cristallographie des calculs urinaires. Aspects néphrologiques et urologiques. *Encycl Méd Chir (Elsevier, Paris)*. Néphrologie-Urologie 1999; 18-104-A-25:1-17.

7. Rodman JS. Management of uric acid calculi in the elderly patient. *Geriatric Nephrol Urol* 1991; 1:129-137.

8. Daudon M. Comment analyser un calcul et comment interpréter le résultat. *L'Eurobiologiste* 1993; 203:35-46.

9. Daudon M, Bounxouei B, Santa Cruz F, Leite Da Silva S, Diouf B, Angwafo III FF et al. Composition des calculs observés aujourd'hui dans les pays non industrialisés. *Prog Urol* 2004; 14:1151-1161.

10. Jabouirik F, Aitoumar H, Belhadj MH. Lithiase urinaire de l'enfant: Analyse chimique a propos de 47 cas. *Rev Maghr Pédiatr* 2003; 13:289-294.

11. Harrache D, Mesri Z, Addou A, Semmoud A, Lacour B, Daudon M. La lithiase urinaire chez l'enfant dans l'ouest algérien. *Ann Urol* 1997; 31:84-5.

12. Daudon M. L'analyse morphoconstitutionnelle des calculs dans le diagnostic étiologique d'une lithiase urinaire de l'enfant. *Arch Pédiatr* 2000; 7:855-865.

13. Jallouli M, Jouini R, Mekki M, Belguith M, Najjar ME, Nouri A. Particularités de la lithiase urinaire du nourrisson en Tunisie. A propos de 64 observations. *Prog Urol* 2004; 14:376-9.

14. Alaya A, Belgith M, Jouini R, Nouri A, Najjar ME. La lithiase urinaire de l'enfant en Tunisie. Aspects actuels à propos de 104 cas. *Prog Urol* 2006; 16:474-480.
15. Alaya A, Nouri A, Najjar ME. Paediatric renal stone disease in Tunisia: A 12 years experience. *Arch Ital Urol Androl* 2008; 80:1-6.
16. Daudon M. Évolution de la composition et de la localisation des calculs chez le sujet âgé. *Feuillets de Biologie* 2003; 25:51-4.
17. Kamoun A, Daudon M, Abdelmoula J, Hamzaoui M, Chaouachi B, Houissa Tet al. Urolithiasis in Tunisian children: a study of 120 cases based on stone composition. *Pediatr Nephrol* 1999; 13:920-925.
18. Daudon M. Les lithiases urinaires secondaires à des maladies héréditaires. *Biologie et Santé* 2001; 1:141-156.
19. Biggs AW, Norflet CM, Garvey FK. Urolithiasis reviews of three hundred cases. *Trans Southast Seek A U S* 1955; 76.
20. Oussama A, Kzaiber F, Mernari B, Semmoud A, Daudon M. Analyse de la lithiase de l'enfant dans le moyen Atlas Marocain par spectrométrie infrarouge. *Ann Urol* 2000; 34:384-390.
21. Cachat F, Barbey F, Guignard JP. Epidémiologie de la lithiase urinaire chez l'enfant. *Rev Med Suisse Romande* 2004; 124:433-7.
22. Daudon M, Doré JC, Jungers P, Lacour B. Changes in stone composition according to age and gender of patients: a multivariate epidemiological approach. *Urol Res* 2004; 32:241-7.
23. Daudon M, Jungers P. Clinical value of crystalluria and quantitative morphoconstitutional analysis of urinary calculi. *Nephron Physiol* 2004; 98:31-36.
24. Rizvi SA, Naqvi SA, Hussain Z, Shanjehan S. Renal stones children in Pakistan. *Br J Urol* 1985; 57:618-621.
25. Jungers P, Daudon M. Formes cliniques de la lithiase urinaire: lithiase de l'enfant. In: Jungers P, Daudon M, Le Duc A, editors. *Lithiase urinaire*, Paris: Flammarion Médecine-Sciences; 1989; p. 357.



Correspondence

Akram Alaya, MD
Department of Biochemistry and Toxicology
University Hospital, 5000 Monastir, Tunisia
akram_alaya@yahoo.co.uk

Abdellatif Nouri, MD
Department of Pediatric Surgery
University Hospital, 5000 Monastir, Tunisia
nouri.abdellatif@rns.tn

Mohamed Fadhel Najjar, MD
Department of Biochemistry and Toxicology
University Hospital, 5000 Monastir, Tunisia
najjar.fadhel@rns.tn

Calcium oxalate nephrolithiasis: Urinary “medium size peptides” analysis using MALDI-TOF mass spectrometry.

Alessandro D'Addessi¹, Luca Bongiovanni¹, Matteo Vittori¹, Chiara Fanali², Nazario Foschi¹, Massimo Castagnola², Pier Francesco Bassi¹

¹Department of Urology;

²Department of Biochemistry Catholic University Medical School, Rome, Italy

Summary

Objective: Urinary lithiasis is one of the most common benign urological diseases. The pathogenic mechanisms of renal stone formation are complex and not clearly defined. We have studied the urinary protein composition of patients affected by calcium oxalate (CaOx) nephrolithiasis in a range of molecular weight between 1 and 5 kDa (medium size peptides). These molecules seem to have a double role in limiting the crystal adhesion to renal cells and at the same time in facilitating the degradation of crystals once internalised in cells. Their daily excretion is high, approximately 2-7 mg/die, even if studies have reported higher values. Our aim in surveying the urinary peptides was to look for qualitative difference in the medium size range, possible indication of the presence of a biomarker or any predisposing factors in patients affected by calcium oxalate nephrolithiasis.

Materials and methods: The urinary protein composition of 17 patients (11 male, 6 female; mean age 45 yrs \pm 14SD) affected by CaOx nephrolithiasis was assessed in comparison with 17 healthy subjects. It was performed a qualitative assay using MALDI-TOF mass spectrometry (MS) in a range of molecular weight between 1 and 5kDa (medium size peptides).

Results: No differences were detected in the mass spectrums between patients and control subjects: all peaks overlapped. In addition, the values of peak intensity were comparable in both patient and control subject mass spectrums.

Conclusions: In the range of molecular weight between 1 and 5 kDa, we have not detected significant differences in the urinary composition between stone former patients and healthy subjects. Our results warrant further research in different molecular size peptides.

KEY WORDS: Nephrolithiasis; Proteins; Renal Stones; Urine, Proteomics; Peptides; MALDI-TOF

Submitted 8 September 2009; Accepted 15 December 2009

INTRODUCTION

Urinary lithiasis is one of the most common benign urological diseases. It affects the health of the entire world population, that is to say no geographical area, or cultural or ethnic group has been known to suffer to any greater or lesser extent (1). The annual incidence of nephrolithiasis estimated in Europe and North America is 0.5% (2).

In the United States, the prevalence grew from 3.2% to 5.2% respectively from the mid-1970s to the mid-1990s (3).

The risk of developing urinary stones throughout one's lifetime stands at 15%. The risk of recurrence is 50% in the first 5-10 years, increasing to 75% in 20 years (4).

In recent years, there has been a new growing interest in urinary lithiasis. The exact series of biological events from urinary supersaturation to crystallization, and final-

ly to stone formation has not been thoroughly defined yet. It is expected, however, that proteins and peptides are critical mediators of the crystallization process, but there is no clear evidence just how they really work in physiopathological pathways (5).

Many investigators are currently analysing crystal-protein interactions in fresh human urine, in in vitro kidney cell lines and in the stone matrix using proteomic and molecular biology (6).

The different origins of proteins which have been identified in the stone matrix (i.e. extracellular, intracellular, membrane proteins) attests to the complex and multifactorial pathogenesis for stone formation (7).

Nevertheless, a well-defined pathological approach to the disease remains complex. The clinical approach is

also quite difficult, particularly in the management of recurrences. With the exclusion of patients suffering from predisposing diseases (metabolic or otherwise), detectable from radiological or laboratory tests, many patients have not revealed any physiopathological/metabolic alterations that justify the "stone forming status" and recurrences of the disease.

Nowadays, a marker of the disease is as of yet unavailable. Prevention, therefore, cannot take place as it is not feasible to clearly identify those subjects who are predisposed to a first occurrence of urinary stones, as well as recurrences following treatment. In this study, we approached the proteomic analysis assessing the urinary protein composition of patients affected by calcium oxalate (CaOx) nephrolithiasis. We then compared the results with the same number of healthy subjects using a matrix-assisted laser desorption/ionization mass spectrometry (MALDI-TOF), in the mass spectrum between 1 and 5 kDa (medium size peptides).

As proposed by Chauvet and Ryall, intracrystalline urinary proteins < 10kDa probably facilitate intracellular proteolytic digestion and destruction of crystals phagocytised by urothelial cells, so protecting against urolithiasis (8). Keeping in mind the research for signs indicating the possible presence of biomarkers or any predisposing factors in patients affected by CaOx nephrolithiasis, aim of this study was to explore a different urinary proteic section, the so-called "medium size peptides", with a molecular weight ranging from 1 to 5 kDa.

MATERIALS AND METHODS

The patients enrolled in the study were outpatients undergoing extracorporeal shock wave lithotripsy treatment (SWL) who joined our Institution.

The only inclusive criterion was the presence of renal radiopaque stones < 15 mm in diameter. Exclusion criteria included: recent episodes of renal colic (less than 3 months), to avoid a bias concerning the occurrence of acute phase proteins and other molecules released because of damage to urothelial cells; the presence of radiolucent lithiasis to avoid a bias regarding the composition of stones; renal impairment; upper urinary tract obstruction and malignancy. With regards control subjects, healthy individuals were selected on the basis of a close comparison in terms of age and sex to patients. Furthermore, these subjects did not suffer from any urinary stones and their renal ultrasound study resulted negative.

Internal Review Board approval of the study was obtained. We were obliged to inform patients and control subjects of the need to complete an informed consent form. On that basis, therefore, we enrolled 17 patients (Male = 11, Female = 6; mean age 45 yrs \pm 14 SD) and 17 healthy control subjects, performing a close match in terms of age and sex.

Before the SWL treatment, we collected a venous blood sample (dosage of glucose, creatinine, urea nitrogen, uric acid, serum electrolytes, PTH), a sample of urine collected over 24h (dosage of urinary calcium, phosphate, oxalate, uric acid, citrate), and a sample of urine (from the second micturition in the morning) in order to carry out a proteomic study. Therefore, all patients were treat-

ed using the SWL, with a request from ourselves to deliver debris expelled, in order to allow us make a detailed crystallographic analysis. From the control subjects, we only collected a sample of urine for the proteomic study.

Urine sample collection, handling and storage

Regarding urine collection, a sample from the second micturition in the morning was taken. All samples were centrifuged in a refrigerated centrifuge (2000 g for 10 minutes) to eliminate any cellular fraction. The supernatants were centrifuged (5000 g for 10 minutes) to eliminate particles and the limpid supernatants were finally stored at -80°C until analysis.

Preparative magnetic purification, desalting step and MALDI-TOF analysis

5 μ l of supernatant of each sample and 10 μ l of binding solution were placed in standard thin-wall PCR tubes, 5 μ l of MB-C8 suspension of magnetic beads were then added and carefully mixed (Care MB-HIC 8, [magnetic bead-hydrophobic interaction chromatography], Bruker Daltonics, Bremen, Germany). The tubes were then placed in a magnetic bead separator and, after 30 seconds, the supernatant was carefully removed and discarded. The beads were washed three times in 100 μ l of washing solution. The bound peptides were then eluted from the beads with 5 μ l of 50% acetonitrile.

The peptides eluted from the beads were premixed 1:1 with matrix solution (5 g/L cyano-4 hydroxycinnamic acid in 50% acetonitrile/0,1% trifluoroacetic acid), deposited onto a stainless steel target according to the dried droplet method and analyzed using a MALDI-TOF MS (Bruker Daltonics Autoflex mass spectrometer, Bremen, Germany). MALDI-TOF mass spectrums were acquired with a pulsed nitrogen laser (337 nm) in linear mode. In positive linear mode, spectrums were obtained with an ion source of 19 kV, a pulsed ion extraction time of 150 ns, a detector gain voltage of 1400V and laser frequency 5 Hz. The final mass spectrums were produced by averaging 500 laser shots to improve the signal-to-noise ratio. Calibration was performed using Angiotensin I and II, substance P and Bombesin.

The matrix used was the same for both patient and control subject analysis. Peak lists and signal intensity of each mass were created and automatically calculated based on the sophisticated numerical annotation procedure algorithm using the FlexAnalysis 2.0 software (Bruker Daltonick, Bremen, Germany).

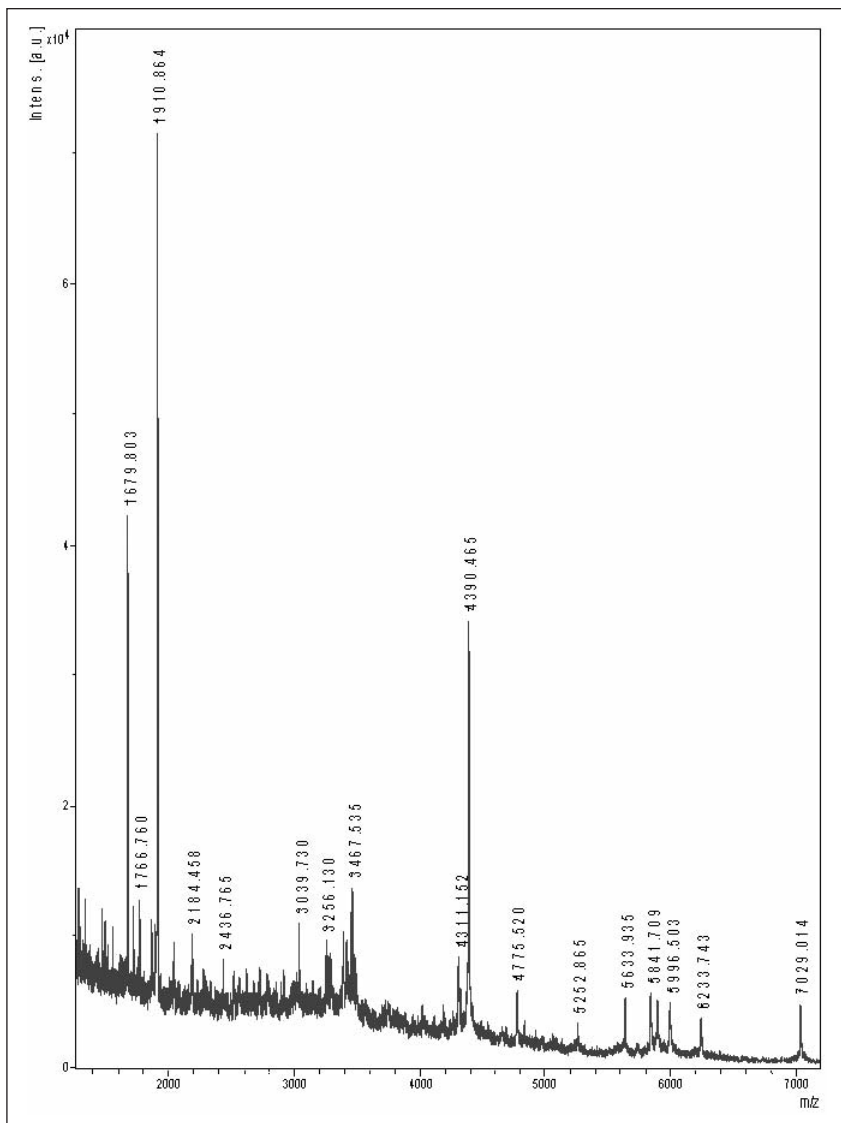
The data was further processed according to the ClinProt tool program: the raw spectrums were normalized to their own total ion count and then calibrated once again using the most prominent peaks. The baseline was then subtracted to allow detection of peaks.

RESULTS

Of the 17 patients enrolled, none showed any signs of organic abnormalities of the urinary tract in the radiological tests carried out, or any alterations in blood chemistry tests. In all patients, serum creatinine and BUN levels were respectively in the range of 0.5-1.2 mg/dl and < 23 mg/dl. Two patients showed an increased

Figure 1.

A mass spectrum of a female stone patient 21 years old. Molecular weight of peptides are expressed as the m/z ratio (m = mass, z = electric charge). Y-axis reports the intensity of each peak according to a scale based on an arbitrary units (a.u.).



urinary oxalate dosage, while two others had a lower concentration of urinary citrate.

The CaOx composition of all stones was defined from the crystallographic analysis of the stone debris expelled by the patients after shock wave lithotripsy treatment.

MALDI-TOF mass spectrums for each patient and his/her control (matched in terms of age and sex), were acquired. No significant differences in the patients and control subject mass spectrums were detected: all peaks overlapped (Figure 2). Furthermore, the values of peak intensity are comparable in both the patients mass spectrums and those of the control subject ones.

DISCUSSION

The pathogenic mechanisms of renal stone formation are complex and not clearly defined.

A better definition of urinary proteome was recently obtained by Adachi *et al.* (9), with the identification of 1.543 proteins. Urines are rich in extracellular proteins, plasmatic membrane proteins and lysosomal proteins, while other intracellular proteins are poorly represented. It was expected that urine contains many extracellular proteins, for definition; however, the presence of plasmatic membrane proteins and lysosomal proteins was not expected.

Pathophysiological changes in the genitourinary tract and kidneys are reflected by changes in the urinary proteome.

Urine is a sampling of all the plasma proteome, but with a significant bias due to the physiology of urine formation, taking into consideration the peptides and proteins added to the urinary tract (10-15).

Notably, the urine/plasma ratio of concentrations for most proteins with the size of albumin, or even larger is less than 0.001, while the ratios of smaller proteins and peptides are usually closer to 1: urine, compared with plasma, is approximately 1000-fold enriched in low-molecular-weight proteins and peptides relative to large plasma protein components (16).

A MALDI-TOF mass spectrometry can, at the same time, provide the mass of all the molecules absorbed in the matrix, in a range that is more or less widely established by the operator. A MALDI-TOF does not perform a quantitative analysis but a qualitative one: the intensity of the peaks depends generally on the interaction between the matrix and the peptide.

The MALDI-TOF is indicated to detect markers of the disease, and it may solve a complex sample providing data regarding the molecular masses of all proteins inside. Another great advantage is that the spectrums may be compared to other spectrums obtained from different samples in order to assess any differences. Urine sample assessment in the range of 1-5kDa, using a MALDI-TOF mass spectrometer, has allowed us to explore a particular section of the urinary proteome in patients suffering from urinary stones: medium size peptides.

We have studied medium size peptides because progressively data of a close relationship between these peptides and urinary lithiasis are emerging in literature. Their daily excretion is high, approximately 2-7 mg/die, even if other studies have reported higher values (17-19). To determine how urinary proteins influence the physiopathogenetical pathway, Chauvet and Ryall (8) investigated the

cultured renal cell assuming that urinary proteins play a dual protective role preventing the contact of the crystals and at the same time promoting and facilitating the process of internalization of the crystals. They showed that intracrystalline proteins of molecular weight < 10 kDa played an important role in the intracellular proteolytic digestion and destruction of crystals phagocytised by urothelial cells. Close to the processes of intracellular destruction of the crystals, extracellular degradation processes were also described, suggesting that extracellular proteases could play a central role in the destruction of the crystals formed in biological fluids.

The physiopathological approach to urinary lithiasis has acquired various proteins as inhibitors of stone formation, both soluble protein and membrane receptors [bikunin (20), osteopontin (21), fragments of prothrombin (UPTF-1) (2), Tamm-Horsfall protein (23-25), trefoil factor 1 (26), phosphatidylserine (27), NRP (nucleolin-related protein) (28), hyaluronate (29) and annexin II (30)].

Chen *et al.* (31) extracted low molecular weight proteins from CaOx stones and measured their characteristic patterns using a mass spectroscopy. Three bands of proteins were identified. The most frequently observed proteins from band 1 (27 kDa) were leukocyte elastase precursor, cathepsin G precursor, azurocidin precursor, and myeloblastin precursor (EC 3.4.21.76) (leukocyte proteinase 3); while band 2 (18 kDa) comprised calgranulin B, eosinophil cationic protein precursor, and lysozyme C precursor; and band 3 (14 kDa) showed neutrophil defensin 3 precursor, calgranulin A, calgranulin C, and histone H4.

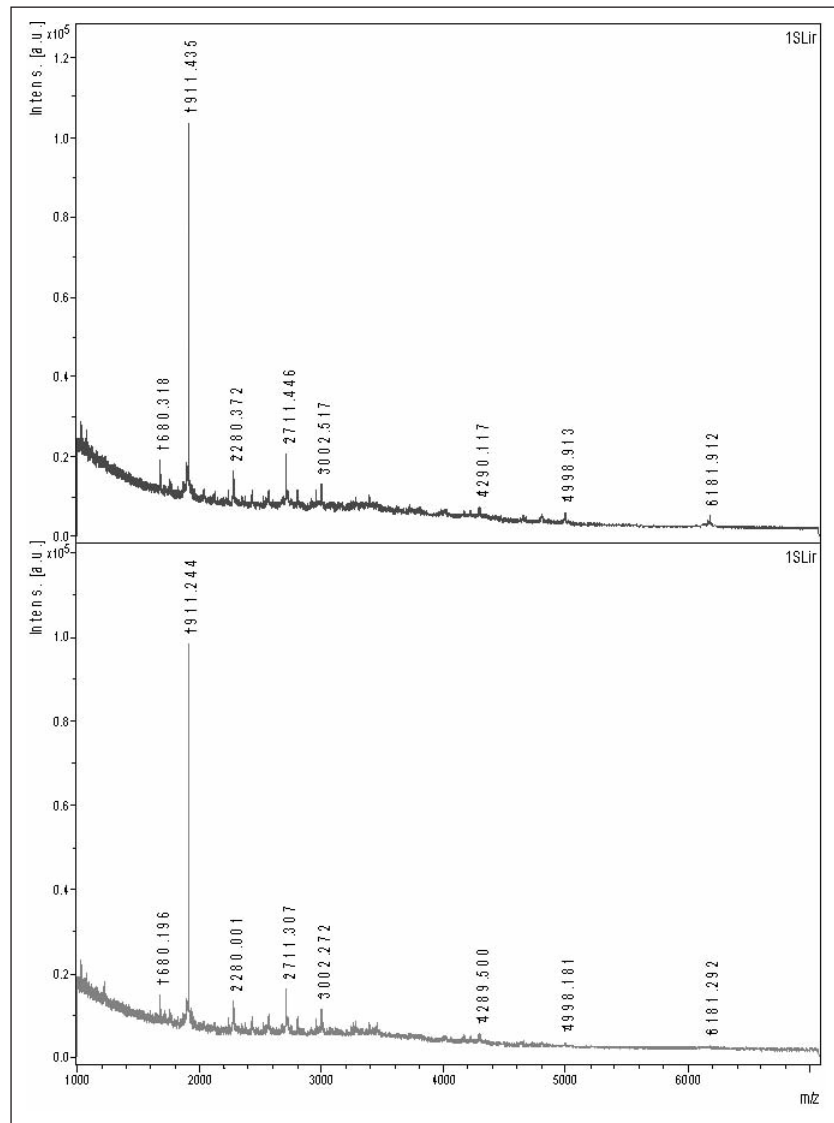
Canales *et al.* (6) using a comprehensive proteomics approach, identified more than 70 proteins from 7 pure CaOx stones, with a high relative abundance of inflammatory proteins (clusterin, defensin, lactoferrin, eosinophilic cationic protein, and limitrin), in addition to the expected urinary and cellular proteins.

The present evaluation of the medium size peptides in the urine of the stone former patients didn't seem to confirm significant differences with the urine of healthy subjects. What seems to have emerged from *in vitro* and *in vivo* studies, is that a delicate equilibrium, based on many pathways regulated by the function of proteins and soluble peptides, membrane proteins and intracellular mechanisms, exists.

All or any of these pathways could make a subject more susceptible to the recurrence of urinary stones.

Figure 2.

A comparison between the mass spectrums of a patient (blue line) and of a healthy subject (red line) cross-matched for age and sex (female, 55 years). The spectrums are acquired in a linear mode (SLin). Molecular weights of peptides are expressed as the m/z ratio and the y-axis reports the intensity of each peak according to a scale based on arbitrary units (a.u.).



CONCLUSIONS

The analysis of urinary peptides < 5 kDa we made in our study failed to detect significant differences between the urine of stone former patients and the urine of healthy subjects and, consequently, no signs of possible biomarkers or any predisposing factors have been found in stone former patients.

Further researches are requested in order to explore a different proteic section, so focusing a mass spectrometry analysis on protein > 5 kDa.

REFERENCES

1. Bichler K, Stromhaier W, Korn S. Urolithiasis in childhood. *Monatsschr Kinderheild* 1985; 133:256-76.
2. Pak CY. Kidney stones *Lancet* 1998; 351:1797-801.

3. Stamatelou KK, Francis ME, Jones CA, Nyberg LM, Curhan GC. Time trends in reported prevalence of kidney stones in the United States: 1976-1994. *Kidney Int* 2003; 63:1817-23.
4. Trinchieri A, Ostini F, Nespoli R, Rovera F, Zanetti G. A prospective study of recurrence after a first renal stone. *J Urol* 1999; 162:27-30.
5. Khan SR, Finlayson B, Hackett RL. Stone matrix as proteins adsorbed on crystal surfaces: a microscopic study. *Scan Electron Microsc* 1983; 1:379-85.
6. Canales BK, Anderson L, Higgins L, et al. Comprehensive Proteomic Analysis of Human Calcium Oxalate Monohydrate Kidney Stone Matrix. *J Endourol* 2008; 22:1161-68.
7. Merchant ML, Cummins T, Wilkey DW, et al. Proteomic analysis of renal calculi indicates an important role for inflammatory processes in calcium stone formation. *Am J Physiol Renal Physiol* 2008; 295:1254-58.
8. Chauvet MC, Ryall RL. Intracrystalline proteins and calcium oxalate crystal degradation in MDCK II cells. *J Struct Biol* 2005; 151:12-17.
9. Adachi J, Kumar C, Zhang Y, Olsen JV, Mann M. The human urinary proteome contains more than 1500 proteins, including a large proportion of membrane proteins. *Genome Biol* 2006; 7:R80.0-R80.16.
10. Brenner BM, Hostetter TH, Humes HD. Molecular basis of proteinuria of glomerular origin. *N Engl J Med* 1978; 298:826-33.
11. Norden AG, Lapsley M, Lee PJ, et al. Glomerular protein sieving and implications for renal failure in Fanconi syndrome. *Kidney Int* 2001; 60:1885-92.
12. Deen WM. What determines glomerular capillary permeability? *J Clin Invest* 2004; 114:1412-14.
13. Christensen EI, Gburek J. Protein reabsorption in renal proximal tubule-function and dysfunction in kidney pathophysiology. *Pediatr Nephrol* 2004; 19:714-21.
14. Gekle M. Renal tubule albumin transport. *Annu Rev Physiol* 2005; 67:573-94.
15. Negri AL. Proximal tubule endocytic apparatus as the specific renal uptake mechanism for vitamin D binding protein/25-(OH)D3 complex. *Nephrology* 2006; 11:510-15.
16. Hortin GL, Sviridov D. Diagnostic potential for urinary proteomics. *Pharmacogenomics* 2007; 8:237-55.
17. Melegos DN, Diamandis EP, Oda H, Urade Y, Hayaishi O. Immunofluorometric assay of prostaglandin D synthase in human tissue extracts and fluids. *Clin Chem* 1996; 42:1984-91.
18. Oda H, Shiina Y, Seiki K, Sato N, Eguchi N, Urade Y. Development and evaluation of a practical ELISA for human urinary lipocalin-type prostaglandin D synthase. *Clin Chem* 2002; 48:1445-53.
19. Mayo Medical Laboratories: Test Catalog. 2006, Rochester, MN, USA.
20. Enghild JJ, Thøgersen IB, Cheng F, Fransson LA, Roepstorff P, Rahbek-Nielsen H. Organization of the inter-alpha-inhibitor heavy chains on the chondroitin sulfate originating from ser10 of bikunin: posttranslational modification of IαI-derived bikunin. *Biochemistry* 1999; 38:11804-13.
21. Asplin JR, Arsenault D, Parks JH, Coe FL, Hoyer JR. Contribution of human uropontin to inhibition of calcium oxalate crystallization. *Kidney Int* 1998; 53:194-99.
22. Stapleton AMF, Ryall RL. Crystal matrix protein: getting blood out of a stone. *Miner Electrolyte Metab* 1994; 20:399-409.
23. Scurr DS, Robertson WG. Modifiers of calcium oxalate crystallization found in urine III: Studies on the role of Tamm-Horsfall mucoprotein and of ionic strength. *J Urol* 1986; 136:505-507.
24. Hess B, Nakagawa Y, Coe FL. A new spectrophotometric method for measuring calcium oxalate monohydrate crystal aggregation in the absence of supersaturation: inhibitory effects of urinary glycoproteins. *Urol Res* 1989; 17:149-50.
25. Grover PK, Moritz RL, Simpson RJ, Ryall RL. Inhibition of growth and aggregation of calcium oxalate crystals in vitro: a comparison of four human proteins. *Eur J Biochem* 1998; 253:637-44.
26. Chutipongtanate S, Nakagawa Y, Sritippayawan S, et al. Identification of human urinary trefoil factor 1 as a novel calcium oxalate crystal growth inhibitor. *J Clin Invest* 2005; 115:3613-22.
27. Bigelow MW, Wiessner JH, Kleinman JG, Mandel NS. Surface exposure of phosphatidylserine increases calcium oxalate crystal attachment. *Am J Physiol Renal Physiol* 1997; 272:F55-62.
28. Sorokina EA, Kleinman JG. Cloning and preliminary characterization of a calcium-binding protein closely related to nucleolin on the apical surface of inner medullary collecting duct cells. *J Biol Chem* 1999; 274:27491-96.
29. Verkoelen CF, Van Der Boom BG, Romijn JC. Identification of hyaluronan as a crystal-binding molecule at the surface of migrating and proliferating MDCK cells. *Kidney Int* 2000; 58:1045-54.
30. Kumar V, Farrell G, Deganello S, Lieske JC. Annexin II is present on renal epithelial cells and binds calcium oxalate monohydrate crystals. *J Am Soc Nephrol* 2003; 14:289-97.
31. Chen WC, Lai CC, Tsai YH, Lin WY, Tsai FJ. Mass spectroscopic characteristics of low molecular weight proteins extracted from calcium oxalate stones: preliminary study. *J Clin Lab Anal* 2008; 22:77-85.

Correspondence

Alessandro D'Addessi, MD
Department of Urology
Catholic University School of Medicine
Largo F. Vito 1 - 00168 Rome, Italy
adaddessi@rm.unicatt.it

Luca Bongiovanni, MD
Policlinico "A. Gemelli"
Largo F. Vito 1 - 00168 Rome, Italy
lucabongiovanni@yahoo.it

Matteo Vittori, MD
Policlinico "A. Gemelli"
Largo F. Vito 1 - 00168 Rome, Italy
matteovittori@inwind.it

Chiara Fanali, MD
Policlinico "A. Gemelli"
Largo F. Vito 1 - 00168 Rome, Italy
chiara.fanali@rm.unicatt.it

Nazario Foschi, MD
Policlinico "A. Gemelli"
Largo F. Vito 1 - 00168 Rome, Italy
nazariofoschi@yahoo.it

Massimo Castagnola, MD
Policlinico "A. Gemelli"
Largo F. Vito 1 - 00168 Rome, Italy
mcastagnola@rm.unicatt.it

Pier Francesco Bassi, MD
Policlinico "A. Gemelli"
Largo F. Vito 1 - 00168 Rome, Italy
bassipf@gmail.com

Urinary alkalization for the treatment of uric acid nephrolithiasis.

Elisa Cicerello, Franco Merlo, Luigi Maccatrozzo

Unità Complessa di Urologia, Ospedale Ca' Foncello, Treviso, Italy

Summary

Three major conditions control the potential for uric acid stones: the quantitative excretion of uric acid, the volume of urine as it affects the urinary concentration of uric acid and the urinary pH. However, the most important factor for uric acid stone formation is acid urinary pH that is a prerequisite for uric acidic stone formation. Indeed the goal standard of urinary alkalization is to achieve a pH of 6-6.5. Administration of alkali should be titrated appropriately by pH paper to record urinary pH until a steady state is achieved. Alkali therapy such as sodium bicarbonate and potassium citrate has been advocated on the basis of established clinical experience, although potassium citrate should be preferred because it may avoid the complication of calcium salt precipitation. Recently it has been reported the clinical efficacy of therapy with potassium citrate/potassium bicarbonate for dissolution of radiolucent stones respect to control study period (only water daily intake of 1500 ml). Furthermore, mean urinary pH was significantly continuously higher during the alkali treatment study in comparison to the control study period, even though the mean of urinary volumes were similar in the two periods. In conclusion urinary alkalization with maintaining continuously high urinary pH values, could be the treatment of choice for stone dissolution and prevention of uric acid stones.

KEY WORDS: Uric acid stones; Urinary pH; Alkalization.

Submitted 9 December 2009; Accepted 15 March 2010

Uric acid calculi account for a significant percentage of urinary stones, although their incidence varies between countries and accounts for 5 percent to 40 percent of all urinary calculi (1-3). *Atsom et al.* reported 75 percent of the stones in Israel were uric acid (4). In another study in the Sudan, 57 percent of stones contained uric acid (5). Although the incidence of uric acid varies from region to region certain patient subgroups have a much higher prevalence of uric acid stones, such as post ileostomy patients where 80% of stones were uric acid (6). Furthermore in patients who have hyperuricemia without gout, the risk of urolithiasis seems somehow less. Therefore, *Yu and Gutman* have shown that in patients with gout the risk of forming uric acid stones is related to the uric acid excretion levels. Of those patients excreting over 1000 mg per 24-hour period, 50 percent have stones; over 900 mg percent, 38 percent; over 700 mg, 34 percent; and over 500 mg, 21 percent (7).

ACID URIC BIOCHEMISTRY

Uric acid is the end product of purine metabolism in

humans and Dalmatan dogs. In the other mammals uric acid is further broken down into allantoin by the enzyme uricase. Allantoin is 10 to 100 times more soluble compared to uric acid. So the loss of uricase activity in humans and Dalmata dogs accounts for acid uric stone formation only in these mammals (Figure 1). The average adult consumes about 2 mg of purine per kilogram of body weight which results in 200-300 mg of urine uric acid daily. Endogenous production is also about 300 mg/day. Total uric acid excretion is about 600 mg/day for an average person. Excretion of xantine and hypoxantine is normally in the range of 10-50 mg per 24-hour period.

One of the critical determinants of uric acid solubility is the urine hydrogen ion concentration. The pK of uric acid is variously quoted as being 5.35-5.75. Figure 2 shows the urine pH on the abscissa, the percent of the total uric acid is free on the ordinant, and a pK 5.57. At this point 50 percent of the total uric acid is free uric acid. The solubility of free uric acid in urine is somehow different in water because of the modulating effect of other cations. At pH 5.0 in urine, therefore, the solubili-

Figure 1.
Reactions leading to uric acid formation.

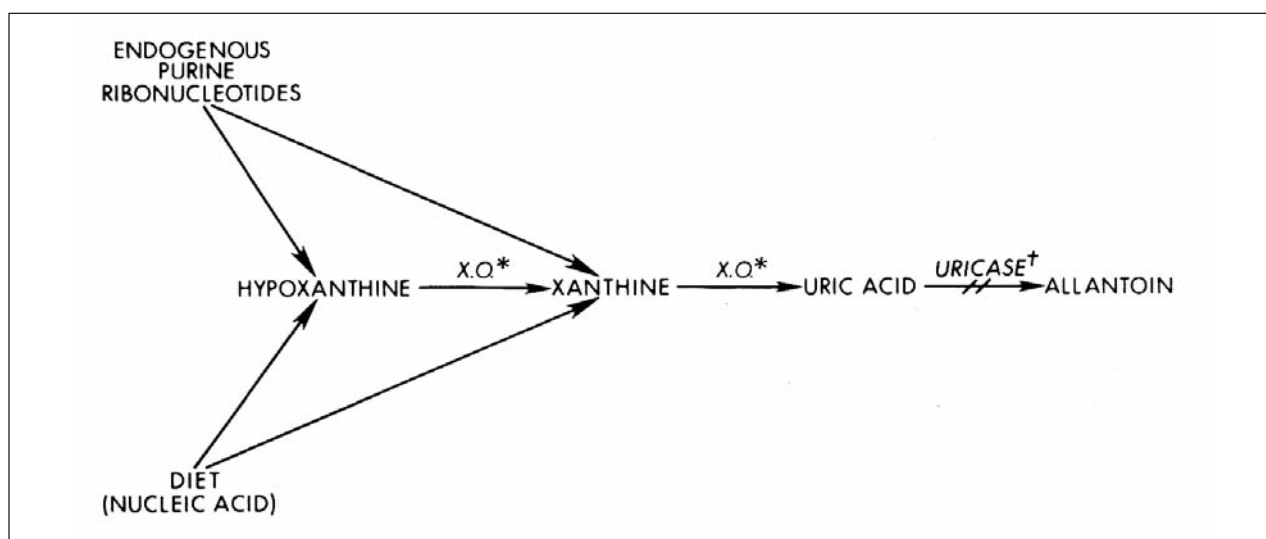
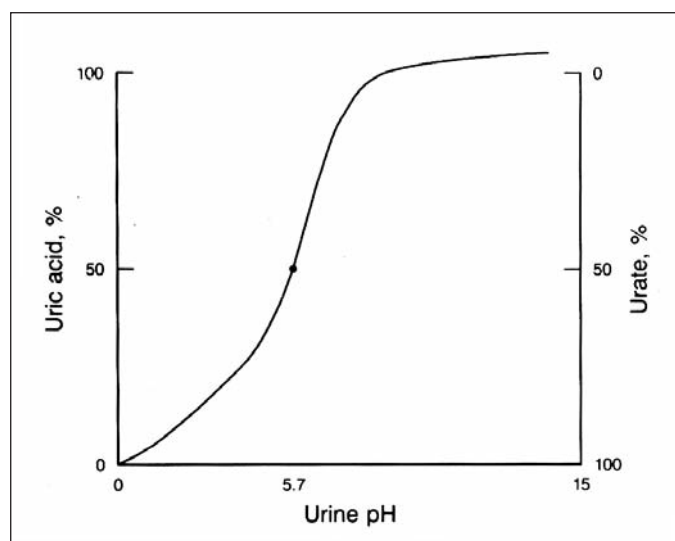


Figure 2.
Correlation of uric acid solubility with urinary pH.



ty of free uric acid is approximately 15 mg/100 ml. However, if the pH is increased to 7.0 the solubility limit is raised to 200 mg/100 ml (8). Similar results are obtained when the solubility of uric acid is determined in water samples rather than urine. At pH 5.0 the solubility limit of uric acid in water is 8 mg/100 ml, while at pH 7.0 the solubility of uric acid is 158 mg/100 ml. Furthermore, it has been reported that a number of factors other than hydrogen ion concentration may be important in determining urate solubility. For univalent salts the solubility of the anion varies inversely with the concentration of the cation. For example, increasing the sodium concentration from 6 to 140 mEq per liter results in more than a twenty-fold reduction of the solubility of urate (9). These other salts of uric acid may rarely precipitate and form stones in urine under certain circum-

stances. Sodium urate may precipitate in the presence of high urate, an alkaline urine pH and high sodium content. Only occasionally does this precipitation result in sodium urate stones, and this usually occurs in patients receiving large sodium and alkali loads with diuretic administration. Ammonium urate stones usually form in conditions of high ammonia and urate excretion, such as in urines infected with urea splitting bacteria.

URINARY pH

A number of studies have documented that patients with uric acid stones excrete a urine that has a lower pH than that control subjects or patients with calcium oxalate stones (7, 10, 11). However, although the finding of a low urinary pH is well documented in patients with uric acid, the basis for this abnormality in acid excretion is not well understood. In fact studies concerning the pathogenesis of persistently acid urine in gout and other uric acid stone patients have led to controversial results. It is known that urine ammonia excretion rates are often low in uric acid stone formers. Since titrable acid excretion is limited by the number of buffers available, this leads directly to abnormality low urinary pHs. Acid loading of ammonium chloride normally provokes a large increase in ammonia production and excretion in normals. It does not increase as much in uric acid stone formers as in normal people (12). Patients with gout also do not get a normal urinary alkaline tide after meals. The alkaline tide is related to the secretion of hydrogen ions in the stomach, which results in increased bicarbonate reabsorption. This bicarbonate is normally excreted by the kidney, increasing urinary pHs (13, 14). This same phenomena is not seen in patients with gout. Furthermore, the lack of diurnal variation in urinary pH has been reported in idiopathic uric acid stone formers and nighttime is considered as high risk time for uric acid stone formation (15).

The exact reason for low ammonia excretion levels in gout or in gouty uric acid stone formers are not known. It is proposed that there is a disturbance of glutamine deamination, which would result in deficient ammonia production and lower available ammonia in the tubular fluid in the distal nephron. Furthermore it is postulated that the loss of the alkaline tide results from a mild metabolic acidosis such as under certain dietary conditions in these patients, which leads to the lower urine pHs (14, 16). The decrease in ammonia excretion is normally about 30 percent, which would decrease total acid excretion by about 15-20 percent. This could be over-come by an increase in titratable acid of about 40-50 percent. Some studies have revealed that there is increased phosphate and titratable acid in these patients. Consequently, net acid excretion is normal over a 24-hour period, but at the expense of lower urinary pHs.

MEDICAL MANAGEMENT OF URIC ACID CALCULI

The therapeutic steps in the management of uric acid stones are based on (1) identification of urinary pH profiles, (2) assessment of urinary volume status, and (3) identification of disorders leading to excessive urate production or excretion.

However, the most important factor for uric acid stone formation is persistently acidic urine that represents a prerequisite for uric acid stone formation and growth. Indeed the goal standard of urinary alkalization is to achieve a pH of 6 to 6.5. Many different agents have been used to alkalize urine and increase uric acid solubility (1). Sodium bicarbonate has been used as a treatment for many years and has the advantage of being inexpensive and generally well tolerated. The usual dose is 650 mg 3 times a day. Commercial baking soda can be used as an alternative and a dose of 1 to 2 tsp. 3 times a day is generally effective (17).

A disadvantage of sodium alkali is increased sodium and fluid load which can be detrimental in patients with congestive heart failure, liver cirrhosis or hypertension. Furthermore, the sodium load may promote calcium oxalate stone formation by increasing urinary excretion of calcium and sodium (18). A combination of sodium bicarbonate and acetazolamide (a carbonic anhydrase inhibitor) has been used to improve urinary alkalization with minimal side effects (19).

Acetazolamide improves urinary alkalization via increased urinary bicarbonate. The induced diuresis prevents sodium and fluid retention. The use of acetazolamide as a solitary agent to produce urinary alkalization is limited. Acetazolamide may increase the risk of calcium phosphate stones by reducing urinary citrate and increasing urinary phosphate excretion. Potassium citrate eliminates the sodium load and has until now been considered first line treatment for uric acid stone dissolution and prophylaxis. Potassium citrate (30 to 60 mEq. per day) has been reported to increase urinary pH from 5.3 to 6.19 and decreases the risk of uric acid stone formation (20).

Accurate selection of the patients is crucial for successful treatment and patients with calcified stones or with insufficient function in the kidney should be excluded (21).

Dissolution of stone can require a prolonged treatment (from 4 weeks to six months) and the compliance of patients is mandatory in order to obtain dissolution of the stones (22, 23).

Recently, *Trinchieri et al.* (24) have been reported the clinical efficacy of potassium citrate/bicarbonate on 8 patients with non-obstructing and asymptomatic radiolucent renal stones (< or = 15 mm) in functioning kidneys. Two study periods were considered: during the first 6 weeks period a daily water intake of 1500 ml was suggested whereas in the following 6 week period the same water intake plus potassium citrate 40 mEq and potassium bicarbonate 20 mEq (divided in two doses). After 6 weeks of potassium citrate bicarbonate therapy (20 mEq twice daily) complete dissolution was found in three of the patients. In the other five cases a partial dissolution was observed and in two of them complete dissolution of the stone was achieved after prolongation of treatment for 4 and 6 months respectively. Furthermore mean urinary pH was significantly continuously higher during the potassium citrate/bicarbonate treatment period in comparison to the first study period even though the mean of urinary volumes were similar in the two groups.

In conclusion medical management with urinary alkalization is the cornerstone of the treatment of uric acid stone in the absence of indications for surgical procedures.

Therefore, prophylaxis with alkali therapy could prevent stone recurrence and can be used as complement of intracorporeal and extracorporeal procedures.

REFERENCES

1. Preminger GM. Pharmacological treatment of uric acid calculi. *Urol Clin North Am* 1987; 1435-8.
2. Shekarriz B, Stoller ML. Uric acid nephrolithiasis: current concepts and controversies. *J Urol* 2002; 168:1307-14.
3. Ngo TC, Assimos DG. Uric Acid nephrolithiasis: recent progress and future directions. *Rev Urol* 2007; 9:17-27.
4. Atsom A, De Vries A, Frank M. Uric acid lithiasis; Amsterdam Elsevier 1963; p6.
5. Ibrahim A, Zein M, Beileil O. Uric acid in the Sudan. *J Trop Med Hyg* 1977; 80:173-6.
6. Yu TF. Urolithiasis in hyperuricemia and gout. *J Urol* 1981; 81:424-30.
7. Yu TF, Gutman AB. Uric acid nephrolithiasis in gout: predisposing factors. *Ann Intern Med* 1967; 76:1133-48.
8. Klinenberg JR, Goldfinger SF, Seegmiller JO. The effectiveness of a xantine oxidase inhibitor allopurinol in the treatment of gout. *Ann Intern Med*, 1965; 62:639-47.
9. Peters JP, Van Slyke KK. Quantitative Clinical Chemistry, 2nd edition, V.1. Baltimore: Williams and Wilkins 1946; p 937.
10. Gutman AB, Yu TF. Uric acid nephrolithiasis. *Am J Med* 1968; 45:756-9.
11. Ito H, Kotake T, Nomura K, et al. Clinical and biochemical features of uric acid nephrolithiasis. *Eur Urol* 1995; 27:324-8.
12. Plante GE, Durivage J, Lemieux G. Renal excretion of hydrogen in primary gout. *Metabolism* 1968; 17:377-85.

13. Henneman PA, Wallach S, Dempsey EF. The metabolic defect responsible for uric acid stone formation. *J Clin Invest* 1962; 41:537-40.
14. Metcalfe-Gibson A, MacCallum F, Morrison RBI, Wrong O. Urinary excretion of hydrogen ion in patients with uric acid calculi. *Clin Sci* 1965; 28:325-42.
15. Gutman A, Yu TF. Urinary ammonium excretion in primary gout. *J Clin Invest* 1965; 44:1474-81.
16. Falls WF Jr. Comparison of urinary acidification and ammonium excretion in normal and gouty subjects. *Metabolism* 1972; 21:43-5.
17. Low RK, Stoller ML. Uric acid-related nephrolithiasis. *Urol Clin North Am* 1997; 24:135-48.
18. Sakhaee K, Nicar M, Hill K, et al. Contrasting effects of potassium citrate and sodium citrate therapies on urinary chemistries and crystallization of stone forming salt. *Kidney Intern* 1983; 24:348-52.
19. Freed SZ. The alternating use of an alkaling salt and acetazolamide in the management of cystine and uric acid stones. *J Urol* 1975; 113:96-9.
20. Pak CYC, Sakhaee K, Fuller C. Successful management of uric acid nephrolithiasis with potassium citrate. *Kidney Int* 1986; 30:422-6.
21. Tung KH, Tan EC, Foo KT. Chemolysis of uric acid stones. *Ann Acad Med Singapore* 1984; 13:620-24.
22. Vermeulen CW, Fried FA. Observations on dissolution of uric acid calculi. *J Urol* 1965; 94:293-6.
23. Moran ME, Abrahams HM, Burday DE, Green TD. Utility of oral dissolution therapy in the management of referred patients with secondarily treated uric acid stones. *Urology* 2002; 59:206-10.
24. Trinchieri A, Esposito N, Castelnovo C. Dissolution of radiolucent renal stones by oral alkalization with potassium bicarbonate. *Arch Ital Urol Androl* 2009; 81:124-7.



Correspondence

Elisa Cicerello, MD

Unità Complessa di Urologia

Ospedale Ca' Foncello

Piazza Ospedale - 31100 Treviso (Italy)

elisa.cicerello@tin.it

Franco Merlo, MD

Unità Complessa di Urologia

Ospedale Ca' Foncello

Piazza Ospedale - 31100 Treviso (Italy)

f.merlo@ulss.tv.it

Luigi Maccatrozzo, MD

Unità Complessa di Urologia

Ospedale Ca' Foncello

Piazza Ospedale - 31100 Treviso (Italy)

lmaccatrozzo@ulss.tv.it

30 minutes high energy transurethral microwave thermotherapy (30 minutes TUMT) for the treatment of chronic urinary retention in patients with ASA II-III-IV.

Mauro Dicuio¹, Stepan Vesely², Tomas Knutson², Jan-Erik Damber²,
Diego Ettore Cuzzocrea³, Christer Dahlstrand²

¹ Department of Urology, Sahlgrenska University Hospital, Göteborg, Sweden and Department of Urology, Ospedale Maggiore CA Pizzardi, Bologna, Italy;

² Department of Urology, Sahlgrenska University Hospital, Göteborg, Sweden;

³ Department of Urology, Ospedale Maggiore CA Pizzardi, Bologna, Italy

Summary

Objective: to investigate if 30-Minutes-TUMT was useful and safe in the treatment of chronic urinary retention due to BOO in patients with ASA II-III-IV.

Material and methods: 19 patients with chronic urinary retention (mean age 73.5 years) were scheduled for TUMT treatment because of absolute or relative contraindications to surgery. According to ASA classification there were 8 patients ASA II, 9 ASA III and 2 ASA IV. Routinely parameters were studied before and after treatment.

Pain and patient's discomfort before, during and after TUMT treatment were registered using the VAS score (visual analogue scale: 0 = no pain and 10 = maximal pain). Urgency, irritation, and "how they feel" were registered at 2 days, 1, 2 and 4 weeks after TUMT using VAS technique.

Results: mean follow-up was 31,6 months (range 24-47), among the 9 responders patients (47,4%) who void normally without need of catheterisation, one patient died 12 months after the treatment for reasons not connected to the TUMT. Six patients (21.6%) failed the treatment and underwent TURP one or two years later (5 were ASA II and one ASA III). Among the 4 of 19 (21.0%) who had intermittent catheterisation after the treatment two died 1 and 2 years later, one has detrusor instability and one continued intermittent catheterisation. VAS during treatment was: 0 minute = 0.0; 5' = 3.1; 15' = 2.9; 25' = 2.8; 2 h after the treatment = 0.3. At 3 years follow up IPSS, QoL and Qmax were still acceptable. No major complication occurred.

Conclusions: 47.4% of the patients responded positively to the new 30 minutes TUMT removing the urethral catheter, without needing surgical procedure avoiding the operation risk. 68.4% also improved their QoL. Local anaesthesia and oral/intravenous analgesia were sufficient during treatment. TUMT seems to have no anesthesiological risk. It is an option in patients with high risk of operation.

KEY WORDS: Bladder outlet obstruction; Transurethral microwave thermotherapy; Chronic urinary retention; TUMT.

Submitted 23 February 2009; Accepted 30 June 2009

List of abbreviations:

ASA: American Society of anesthesiologists, operative risk classification score.
TUMT: transurethral microwave thermotherapy.
TURP: transurethral resection of the prostate.
VAS: visual analogue scale.
PRV: post residual voided volume.
LUTS: lower urinary tract symptoms.
BPH: benign prostatic hyperplasia.
Qmax: maximum flow rate obtained during free-flow measurement.
PSA: prostate specific antigen.
BOO: bladder outlet obstruction.

INTRODUCTION

The literature concerning alternative options for patients with chronic urinary retention due to BOO is not comprehensive. Nowadays minimally invasive treatments for LUTS and BPH are well studied especially regarding TUMT (Transurethral Microwave Thermotherapy) treatment (1-4), however urinary retention has been considered a relative contraindication (5, 6) even if the recently published updated EAU BPH guidelines recommend that TUMT is also suitable for high risk- patients presenting with recurrent urinary retention (2).

Many patients hesitate to undergo surgical procedures, numerous patients have a high risk to general or spinal anaesthesia. Waiting list for open and endoscopic surgery is also a concern.

The gold standard prostatectomy, both transurethral prostatic resection and open retropubic or transvesical enucleation, have certain risks of morbidity and mortality. Finally, new technologies seem to be very attractive both to patients and to doctors (6).

It is possible to treat patients with the 30-minute TUMT protocol without need of other anaesthesia than local anaesthesia and oral or i.v. analgesia (7).

Studies on transurethral microwave thermotherapy for treating patients in acute urinary retention are limited in number available in literature and in follow up (5, 8).

Djavan et al. have conducted a study suggesting in the preliminary evidence of four months that High Energy-TUMT could be a useful alternative for treatment of acute urinary retention due to BPH with a minimal treatment-associated morbidity, in 94% of the patients it was possible to recover the possibility to void freely at the same rate as after prostatectomy (90% approximately) (5). *Floratos et al.* have evaluated, with a mean follow up of 6 months, the efficacy of High Energy-TUMT, both 2.5 and 3.5 protocol, for treating acute urinary retention due to BPH: 9 of 41 patients underwent re-treatment and 11 of 41 went lost to follow up. However, good responders had improvement in flow, PRV, IPSS and QoL (8).

Acute retention is considered a urological emergency and has been defined as an inability to void with PRV > 300 ml. Significant PVR, absent desire to void and damage of the upper urinary tract are parameters that define the chronic urinary retention, even if the amount of residual urine is not well established (8). To our knowledge no publications on chronic urinary retention and 30 Minutes TUMT (protocol 3.5) exist.

The aim of this study is to evaluate the efficacy and safety of the new 30 minutes software of High Energy-TUMT designed as 3.5 for treating chronic urinary retention in a prospective study cohort of patients with moderate or severe co-morbidity giving an idea of its usefulness with a mean follow-up of 31,6 months.

MATERIAL AND METHODS

A total of 19 patients (mean age 73.5 years, range 56-88) with chronic urinary retention because of LUTS due to BOO were treated in the Sahlgrenska University Hospital from October 1999 to February 2000 in a single session TUMT treatment of 30 minutes using the Prostatron device TUMT 3.5 (*Edap Technomed, France*). All the

patients had relative or absolute contraindications to surgery (e.g. *angina pectoris, severe obstructive pulmonary disease, congestive heart failure*). According to the American Society of Anesthesiologists, operative risk classification score (ASA) was: ASA II for 8 patients, ASA III for 9 patients and ASA IV for 2 patients.

Initial patient evaluation consisted of anamnesis, urological visit including digital rectal examination and history of the patient taken from his clinical journal.

Routine blood chemistry included PSA, hemoglobin and creatinine.

Prostate size was assessed by transrectal ultrasonography (TRUS) and the prostatic volume calculated using the formula considering: length x width x height x $\pi/6$.

Urethrocystoscopy was performed on all the patients with rigid or flexible cystoscope.

If prostatic malignancy was suspected, prostatic biopsy was done. Nine patients underwent urodynamic evaluation before treatment (*Pressure/Flow Study*). Ten patients refused urodynamic study.

The system for TUMT consists of a microwave generator, a urethral treatment microwave antenna and a rectal probe. A computer software (*Prostasoft 3.5*) with a maximum delivery of 80 W of microwave energy controlled the microwave generator and the cooling system in response to preset temperatures of the rectal and urethral thermosensors. Treatment time is 30 minutes.

The correct position of the treatment catheter was checked by transrectal ultrasound.

During the treatment it is allowed to reach a maximum temperature of 44.5 °C in the urethra and 42.5 °C in the rectum.

All TUMTs were administered on a dedicated out-patient basis.

No general or spinal anesthesia was used in the TUMT group with the exception of intra-urethrally applied lidocaine hydrochloride jelly (*Xylocaine® 2%, Astra, Sweden*) and drug cocktail.

Drug cocktails included: paracetamol tablets 500 mg (*Panodil®*), tolterodin L tatarate (*Detrusitol®*) 2 mg, morphine intravenous 2 mg, dextropropoxyphen tablets 50 mg (*Dexofen®*) or diclofenac 50 mg (*Voltaren®*) and norfloxacin 400 mg (*Lexinor®, Astra, Sweden*) (7).

If necessary, additional morphine was given during the treatment, 1-2 mg each time, maximum dose 10 mg.

After treatment, paracetamol tablets 500 mg were given twice a day and norfloxacin 400 mg twice a day for 5 days. After treatment, the patient was discharged if he voided adequately, if not a silicon Foley urethral catheter (14 or 20 Ch) was placed and left for 7 days or more.

During the TUMT treatment we investigated the pain according to the VAS (visual analogue scale) score: 0 (no pain) and 10 (worst imaginable pain) at 0 minutes and at 5, 15, 25 minutes during the treatment and 2 hours after it (7, 9-14).

Urgency, bladder and urethral irritation and the question "how they feel" were investigated with the same technique as we use routinely 2 days and 1, 2 and 4 weeks after treatment.

Conventional statistical methods were used to calculate the mean and standard deviation using computer software.

Table 1.
VAS during treatment.

Pain 0 min	pain 5 min	pain 15 min	pain 25 min	pain 2 hour
0,2 ± 0,6	3,0 ± 2,1	3,0 ± 2,1	3,0 ± 2,2	0,6 ± 1,1
Range: 0-3	range: 0-8,7	range: 0-7,5	range: 0-8	range: 0-7

Differences between values and different parameters were calculated using Wilcoxon Signed Rank test comparisons (15).

Figure 1.

Pain during treatment according to the VAS system.

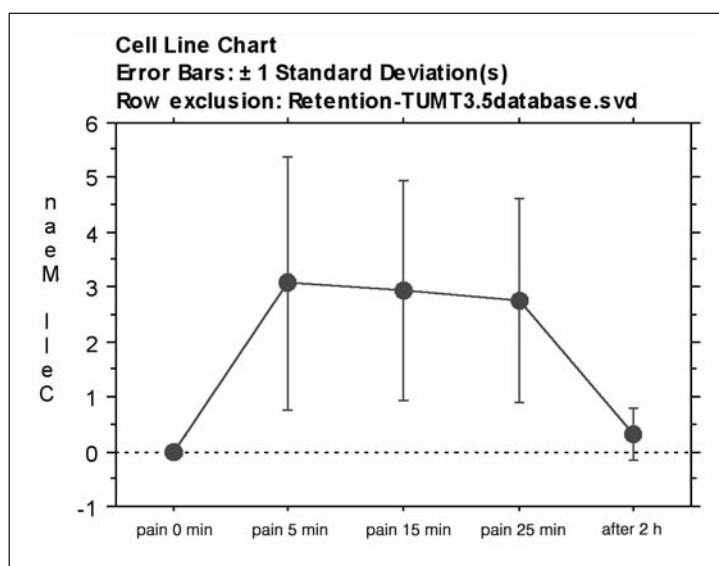
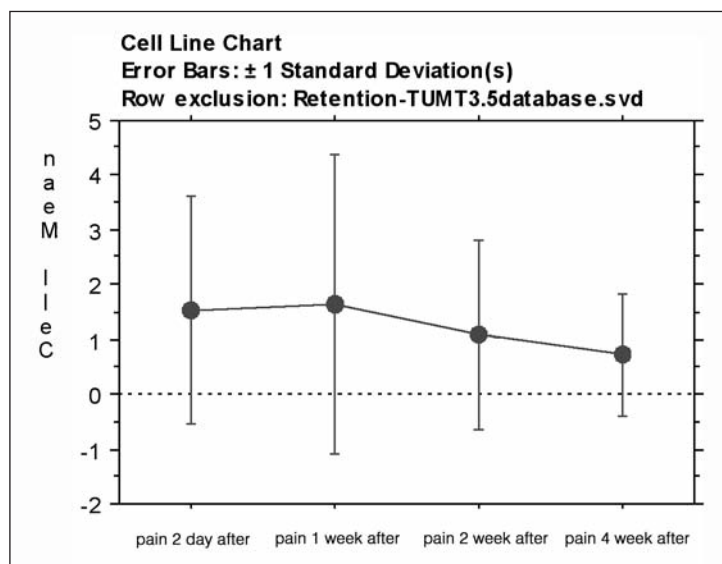


Figure 2.

Pain evaluation 2 days, 1-2-4 weeks after the treatment according to the VAS system.



RESULTS

Nineteen patients (mean age 73.5 years, range 56-88) entered this study, missing data of objective parameters before and after treatment were due to technical problems connected to the urinary retention or because the patient refused additional investigation. Mean catheterisation time previous to treatment was 8.4 months, range 2-18.

IPSS was not determined during urinary retention. The mean prostate volume determined by ultrasound was 51cc (range 23-87cc).

Before treatment, detrusor instability was present in 5 of 9 patients investigated (55.6%), uninhibited overactive bladder in 2 patients (22.2%). No weak detrusor has been recorded. All the patients proved to be obstructed.

Blood chemistry revealed: PSA 5.5 ng/ml, range 0.5-14; hemoglobin 140.3, range 117-160; creatinine 119.8, range 80-196.

Thirteen patients underwent prostate biopsy which were cancer free.

All the TUMT-patients were treated with no need of hospitalisation, after treatment they rested 3-4 hours in the outpatient clinic. Energy delivered was: 118.7 KJ (range 48-136).

No severe complication occurred. Analysis of pain during the treatment is shown in Table 1 and in the cell line chart both with one standard deviation.

Statistically significant differences were found between minute 0 and minute 5, $p < 0.0001$.

Additional request of morphine, usually administered 1-2 mg at each request with a maximum of 10 mg, has been used in 5 (26.3%) of the patients during the treatment.

Complications of the TUMT group were: acute secondary retention occurred in 18.2%, hematuria in 18.2%, urinary tract infections in 18.2%. Forty-five percent of the patients complained during the time with Foley indwelling catheter of bladder spasms with urine leakage.

Perineal discomfort occurred in 65% in low-moderate manner.

All these complications have been resolved within the first 4 weeks.

After treatment, 83.3% of the patients had a silicon Foley catheter 14 or 20 Ch as they were not immediately able to void. Post-treatment morbidity of microwave thermotherapy includes a rapidly developed oedema in the prostate, and catheterisation for up to 2 weeks is usually required.

The mean post-treatment catheter time was 2 weeks, mean post residual urine at removal of catheter was 268 ml, range 19-500. Forty-two percent of the patients needed new catheterization when the catheter was removed at the first attempt.

Treatment failure was considered if the patient was not able to void.

Mean follow up was 31.6 months with a range of 24-47: 9 of 19 patients (47.4%) voided normally without need of catheterization. Six patients (21.6%) failed the treatment, 4 of 19 (21.0%) patients need intermittent catheterization once or twice per day but could void in between. No major complication occurred. Among the 4 of 19 (21.0%) who had intermittent catheterisation after the treatment two died 1 and 2 years later for problems not correlated to the TUMT treatment, one has detrusor instability and one continued intermittent catheterisation. Three patients (*all ASA II*) underwent TURP 5, 8 and 11 months after TUMT.

Mean Qmax and PVR 12 weeks after treatment were respectively: (13.1 ml/s and 158 ml). IPSS and quality of life were respectively (12.1 and 2.4).

In the cell line chart, Figures 2, 3, 4 and 5, pain, urgency, irritation and "how they feel", respectively, are shown according to the VAS system 2 days and 1, 2 and 4 weeks after the treatment with one standard deviation.

DISCUSSION

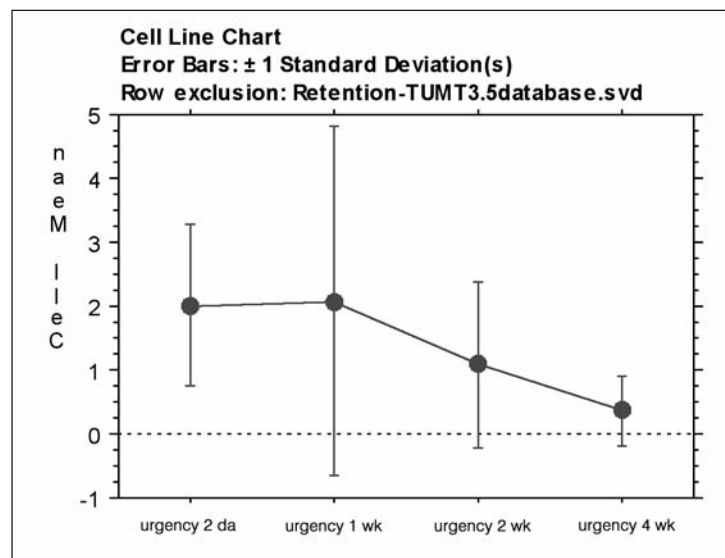
To our knowledge, no studies are available to provide preliminary evidence that 30 Minutes TUMT is an alternative option to prostatectomy in unselected patients with chronic urinary retention and ASA II, III or IV.

In a prospective randomized trial comparing TUR-P and laser therapy in men with chronic urinary retention (*the CLasP Study*) (16) the authors showed that TUR-P remains the treatment of choice because of its superior effectiveness while laser therapy had a decreased risk of complications and shorter hospital stay. However, several complications occurred in the CLasP Study during hospital stay (septicemia, symptomatic urinary tract infection, blood transfusion, confusion).

This study with a mean follow up of 32 months, if compared to Djavan's study (limited length of follow up) and to Floratos's study (mean follow up 6 months), shows the durability of this treatment (5, 8). We lost 2 patients because of unrelated diseases and high age (84 and 86 years). Floratos *et al.* treated patients with acute urinary retention with high energy TUMT obtaining good responses at 12, 26 and 52 weeks Qmax of 15, 11 and 15 ml/s; IPSS of 7, 5 and 2, PVR of 61, 8 and 35 cc, respectively; QoL of 1 at all visits. The re-treatment rate after 1 year was 25%, thus very similar to our results (8).

Lim's study has analysed the outcome of patients in acute urinary retention due to BPH after the removal of the catheter, 58% of the patients were

Figure 3.
Urgency evaluation 2 days, 1-2-4 weeks after the treatment according to the VAS system.



successfully relieved of their catheter without any treatment 24 hours and 48 hours after admission (17).

The risk factors for failure were PVR more than 800 ml and high PSA value.

Thus it is difficult to compare studies of acute and chronic retention.

Still, the number of non responder is high if compared to other studies (80% of the patients were successfully relieved of their indwelling catheter) (18).

However, in our study, we had a selection of disabled patients with chronic urinary retention.

Generally, as discussed by Floratos *et al.* (8), patients presenting in urinary retention are older with poor health status and they have an increased risk of peri-operative

Figure 4.
Irritation evaluation 2 days, 1-2-4 weeks after the treatment according to the VAS system.

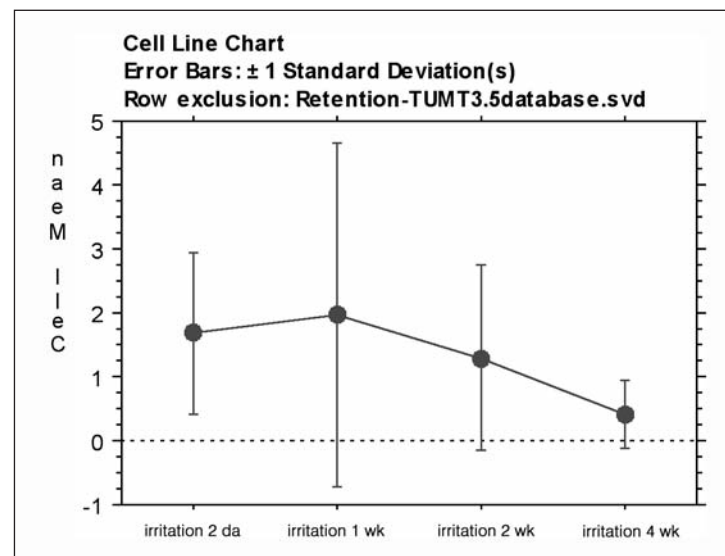
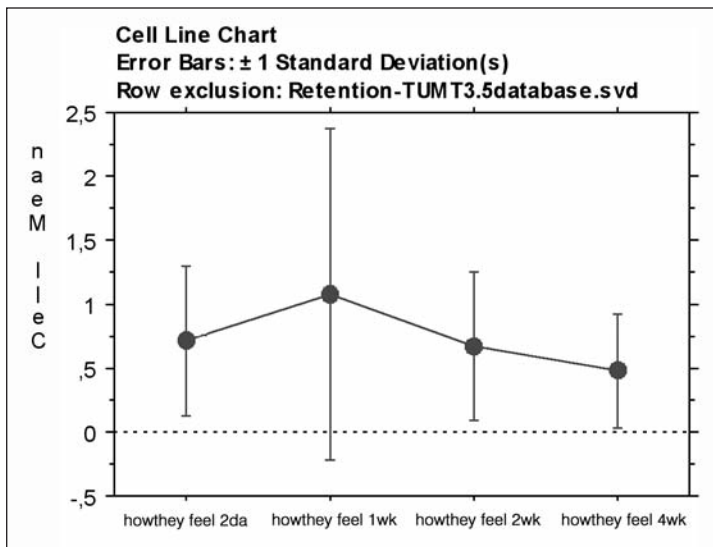


Figure 5.
 "How they feel" evaluation 2 days, 1-2-4 weeks
 after the treatment according to the VAS system in which 0 means
 the best life and 10 the worst.



morbidity and re-operation due to bleeding and mortality. The health status of our patients with chronic urinary retention was worst: we had 57.9% of the patients with ASA III and IV.

Peri-operative complications and mortality of chronic retention are similar to those associated with acute retention.

Treatment failures are directly influenced by advanced age (the mean age of our patients was 73.5 as in Floratos' study), important post void residual urine volume (mean post residual urine at removal of catheter was 268 ml, range 19-500), poor sensation and low bladder compliance (mean catheterization time was 8.4 months) (8). Two non responders showed to have detrusor instability before TUMT treatment.

In our opinion, advanced age and low bladder compliance could be the explanation of the non responder patients. Results obtained during the TUMT treatment show that high energy treatment can be done without the need of the anaesthesiologist in day hospital management. However patient's compliance is still necessary. No difference has been noticed if compared to non high risk patients (19).

The effectiveness and tolerability of thermotherapy 3.5 in 30 minutes allow the opportunity to reduce medication-related side effects, intensive patient monitoring and patient's discomfort. This means that our patients can be discharged a few hours after the treatment. No patients needed hospitalization after TUMT (19).

More than 80% of the patients had mild-moderate pain during the treatment.

Total mean energy delivered was 118.7 Kj, one patient received low energy (48Kj) for unknown reasons.

30 minutes TUMT (3.5 protocol) delivers high energy and it is not comparable to a surgical procedure in the patients in urinary retention but it is a good option in patients with high risk of surgical procedure.

Complication rate is low and no important complication occurred.

In our opinion, the major goals of this study were to underline the number of patients catheter free which we achieved in 47,4% after the treatment and the missing of serious complications even if the treatment failed. We can add the 21,6% of patients who need intermittent catheterisation once or twice per day but could void in between and who feel satisfied, so we can assess that 68.4% of the patients have improved their Quality of Life.

Discomfort and symptoms after treatment connected to quality of life are also important parameters to be investigated. In our study, Pain, Urgency, Irritation and "How they feel" evaluation 2 days, 1, 2 and 4 weeks after the treatment according to the VAS system showed excellent results while IPSS and QoL showed acceptable levels after successful treatment.

CONCLUSIONS

It is possible to treat high surgical risk patients with chronic urinary retention with 30 minutes TUMT without need of other anaesthesia except for local anaesthesia and oral analgesia in the same manner of routine TUMT. The level of pain can be reasonably accepted by all patients. TUMT treatment is a safe option also in patients not suitable for surgery. In this study, 47,4% of the patients responded positively to the new high energy 30 minutes TUMT removing the permanent urethral catheter, without needing a surgical procedure, avoiding the operation risk. Quality of Life and symptom score were also improved for most of the patients.

REFERENCES

1. Vesely S, Knutson T, Dicuio M, et al. Transurethral microwave thermotherapy: clinical results after 11 years of use. *J Endourol* 2005; 19:730.
2. Madersbacher S, Alivizatos G, Nordling J, et al. EAU Guidelines on assessment, therapy and follow up of men with lower urinary tract symptoms suggestive of benign prostatic obstruction (BPH guidelines). *Eur Urol* 2004; 46:547.
3. de Wildt MJ, Wagrell L, Larson TR, et al. Clinical results of microwave thermotherapy for benign prostatic hyperplasia. *J Endourol* 2000; 14:651.
4. de la Rosette JJMCH, Laguna MP, Gravas S, et al. Transurethral microwave thermotherapy: the gold standard for minimally invasive therapies for patients with benign prostatic hyperplasia? *J Endourol* 2003; 17:245.
5. Djavan B, Seitz C, Ghawidel K, et al. High-energy transurethral microwave thermotherapy in patients with acute urinary retention due to benign prostatic hyperplasia. *Urology* 1999; 54:18.
6. Madersbacher S, Marberger M. Is transurethral resection of the prostate still justified?. *Br J Urol* 1999; 83:227.
7. Dicuio M, Knutson T, Vesely S, et al. 30-minutes-TUMT. Use of the visual analogue scale to investigate patients' pain perception, dif-

ferent cocktail options and tolerability during 30 minutes' treatment. *Urol Int* 2004; 73:130.

8. Floratos DL, Sonke GS, Francisca EA et al. High energy transurethral microwave thermotherapy for the treatment of patients in urinary retention. *J Urol* 2000; 163:1457.

9. Chapman CR, Case KL, Dubner R, et al. Pain measurement: an overview. *Pain* 1985; 22:1.

10. De Loach LJ, Higgins MS, Caplan AB, et al. The visual analog scale in the immediate postoperative period: intrasubject variability and correlation with a numeric scale. *Anesth Analg* 1998; 86:102.

11. Scott J, Huskisson EC. Graphic representation of pain. *Pain* 1976; 2:175.

12. Gaston-Johansson E, Gustafsson M. Rheumatoid arthritis: determination of pain characteristics and comparison of RAI and VAS in its measurement. *Pain* 1990; 41:35.

13. Jensen MP, Mc Farland CA. Increasing the reliability and validity of pain intensity measurement in chronic pain patients. *Pain* 1993; 55:195.

14. Roseblum M, Weller RS, Conard PL, et al. Ibuprofen provides longer lasting analgesia than fentanyl after laparoscopic surgery. *Anesth Analg* 1991; 73:255.

15. Colton T. *Statistics in medicine*. Boston: Little, Brown and Company, 1974.

16. Donovan JL, Peters TJ, Neal DE et al. Randomized Trial comparing transurethral resection of prostate, laser therapy and conservative treatment of men with symptoms associate with benign prostatic enlargement: ClasP Study. *J Urol* 2000; 164:65.

17. Lim KB, Wong MY and Foo KT. The outcome of trial off catheter after acute retention of urine. *Ann Acad Med Singapore* 1999; 28:516.

18. Schenlin S. Microwave Thermotherapy in patients with benign prostatic hyperplasia and chronic urinary retention. *Eur Urol* 2000; 39:400.

19. Francisca EAE, Kortmann BBM, et al. Tolerability of 3.5 versus 2.5 high-energy transurethral microwave thermotherapy. *Eur Urol* 2000; 38:59.

Correspondence

Marco Dicuio, MD
Via Morandi 43 - 56124 Pisa, Italy
dicuiomauro@hotmail.com

Stepan Vesely, MD
Department of Urology,
Sahlgrenska University Hospital,
Göteborg SE-413 45, Sweden

Tomas Knutson, MD
Department of Urology,
Sahlgrenska University Hospital,
Göteborg SE-413 45, Sweden

Jan-Erik Damber, MD
Department of Urology,
Sahlgrenska University Hospital,
Göteborg SE-413 45, Sweden

Diego Ettore Cuzzocrea, MD
Department of Urology,
Ospedale Maggiore CA Pizzardi,
largo Bartolo Nigrisoli, 240133 Bologna, Italy

Christer Dahlstrand, MD
Department of Urology,
Sahlgrenska University Hospital,
Göteborg SE-413 45, Sweden

Can Sonovue® targeted biopsy replace extended or saturation biopsy in prostate cancer diagnosis? Our experience at primary and repeat biopsy.

Pietro Pepe, Giuseppe Candiano, Michele Pennisi, Francesco Aragona

Urology Unit, Cannizzaro Hospital, Catania, Italy

Summary

Objective: To evaluate the detection rate of prostate cancer (PCa) at initial and repeat biopsy in patients submitted to Sonovue® targeted biopsy vs extended or saturation prostate biopsy (SPBx). **Material and Methods:** From November 2007 to April 2008 60 patients aged 64 years (median) underwent extended TRUS-guided transperineal prostate biopsy. Indications to biopsy were: abnormal DRE, PSA > 10 ng/mL; PSA included between 2.6 and 4.0 and 4.1 and 10 ng/mL with %free/total PSA ≤ 20% and ≤ 25%, respectively. In 45 and 15 men prostate biopsy was performed as primary and repeated procedure respectively; median PSA was 8.3 ng/mL vs 11.8 ng/mL and digital rectal examination was positive in 9 vs 3 patients, respectively. Before performing extended or SPBx scheme in case of primary (19 cores) and repeated (28 cores) procedure, prostate areas characterized by absence of enhancement after Sonovue® (2.4 mg) administration on gray scale during continuous harmonic imaging (HI) contrast-enhanced ultrasound (CEUS) were considered suspicious for PCa and submitted to targeted biopsy.

Results: 3.5 (median) targeted biopsies were performed in the peripheral zone of 22 men. In patients who underwent primary and repeated biopsy PCa was detected in 20/45 (44.5%) and 3/15 (20%) cases, but Sonovue® detected only 6/20 (30%) and 1/3 (33.4%) of cancers, respectively. Sensitivity and specificity of Sonovue® in diagnosing PCa was equal to 30.0% and 61.5% (primary biopsy) vs 33.4% and 54.5% (repeated biopsy).

Conclusions: Based on its low diagnostic accuracy, Sonovue® CEUS HI targeted biopsy can not replace extended or SPBx in diagnosing PCa.

KEY WORDS: Prostate cancer; Extended prostate biopsy; Contrast-enhanced ultrasound; Targeted prostate biopsy; Microbubble ultrasound contrast agents; Saturation prostate biopsy.

Submitted 23 February 2009; Accepted 30 June 2009

INTRODUCTION

Although the widespread use of PSA in clinical practice has led to an increased diagnosis of prostate cancer (PCa), some patients still remain with a persistent suspicion of harbouring a cancer despite multiple negative biopsies. Nowadays, extended transrectal ultrasound (TRUS)-guided or template biopsy schemes constitute the only suitable method to increase the detection rate of PCa (1).

US diagnosis was enriched in recent years by the introduction of tridimensional and computerized images and by the use of contrast media, which allow better characterization of intraparenchymal microvasculature. Recently, the use of microbubble ultrasound contrast agents (UCA) in diagnosing PCa has been reported (2-4). The microbubble-based UCA have improved flow detection in small vessels and capillaries generating harmonic

signals multiples of fundamental frequency; as the bubbles pass through the blood vessels, changes in the contrast-enhanced image allow a normal tissue to be differentiated from pathological, based on the dynamics of the different microvasculature tissue types. Microbubbles UCA (Sonovue®, Definity®, Imagent®) can be imaged by CDU (colorDoppler ultrasound) and gray scale harmonic imaging but acoustic power associated with conventional ultrasound and Doppler may destroy many bubbles before they reach the external microcirculation. Ultrasound pulse with low acoustic pressure causes a set of harmonics that are received by the transducer allowing to select only signals generated from microbubbles; on the contrary increasing the acoustic pressure causes the microbubbles to burst.

The detection rate of PCa at initial and repeat prostate biopsy in 60 consecutive patients submitted to targeted biopsies after administration of Sonovue® vs extended or saturation prostate biopsy (SPBx) is reported.

MATERIAL AND METHODS

From November 2007 to April 2008 60 consecutive patients aged between 53 and 72 years (median 64 yrs) were submitted to TRUS-guided transperineal prostate biopsy using a biplanar transrectal probe (BK-Med Pro Focus, Copenhagen Denmark) with a tru-cut 18 G needle (Bard; Covington, GA). The SPBx protocol included at least 9 cores in the peripheral zone of each lobe (Apex, Med and Base), beginning parasagittally to reach the lateral margins of the gland and 2-4 cores in the transition zone in case of repeated biopsy. Indications to biopsy were in accordance with a case-finding protocol for the early diagnosis of PCa, whose results have been published elsewhere(5): abnormal digital rectal examination (DRE), PSA > 10 ng/mL; PSA included between 2.6 and 4 ng/mL and 4.1 and 10 ng/mL with %free/total PSA (PSA F/T) < 20% and < 25%, respectively. Prostate biopsy was performed under sedation (propofol) and all patients signed an informed consent form which, in addition to the biopsy-related complications, explicitly reported the complications correlated to the high number of cores and the side effects of Sonovue® (Bracco, Milano, Italy) administration. A third-generation fluorochinolon prophylaxis was prescribed for 8 days, starting the day before the procedure.

In 45 men (75%) prostate biopsy was performed as the primary procedure (1st group) and in 15 (25%) as the second set after an extended scheme (at least 12 cores) with histological findings of normal parenchyma in 13 cases and chronic prostatitis in 2 cases (2nd group). Median PSA was 8.3 ng/mL (range 2.8-24) vs 11.8 ng/mL (range 2.8-44) and digital rectal examination (DRE) was positive in 9 and 3 patients in the first and

second group, respectively. All patients underwent standard TRUS before administration of a bolus of Sonovue® (nonpyrogenic suspension of phospholipid/sulphur hexaphloride) equal to 2.4 mg into a large peripheral vein followed by a flush of saline (10 ml). Before scanning with contrast-enhanced ultrasound (CEUS), an appropriate setup that included low mechanical index (MI) and a split-screen view to display the contrast and B-Mode images at the same time was selected. A timer was activated after UCA injection and the investigation was performed for 200 seconds (median; range 180-240); at the end of the procedure microbubbles were burst. Post-contrast imaging began as soon as contrast medium was visible on gray scale continuous harmonic imaging (HI); the microbubbles normally were distributed throughout the prostate, that appeared contrast-enhanced, and only areas characterized by the absence of Sonovue® enhancement (6) were considered suspicious for PCa (Figure 1). Pre-contrast and post-contrast images were evaluated by an experienced team familiar with contrast enhanced ultrasound of the prostate and at least three targeted cores were performed in suspicious areas after Sonovue® administration. After UCA evaluation and targeted biopsy (when performed) all patients of both groups underwent extended or SPBx taking 19 (median; range 18-22) cores (1st group) and 28 cores (median; range 26-34) cores (2nd group).

For statistical analysis the t Student's - test was used; a p value < 0.05 was considered statistically significant.

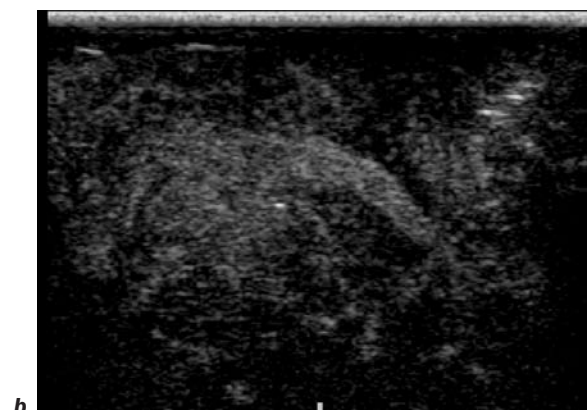
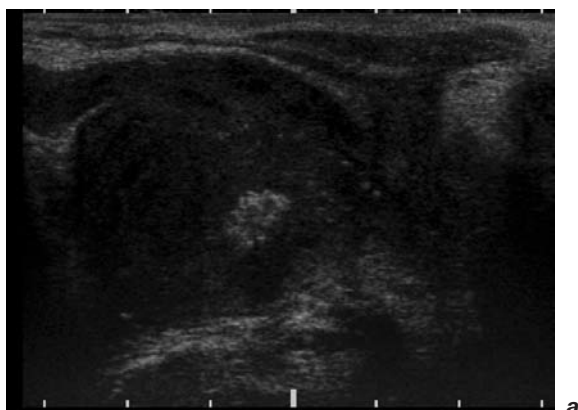
RESULTS

No side-effects were reported after Sonovue® administration; biopsy-related complications were: hematuria in 7 cases (11.7%), acute urinary retention in 5 cases (8.4%), hemospermia in 10 (16.7%) and UTI in 2 cases (3.4%). In 22/60 (36.7%) patients CEUS HI revealed ultrasonic abnormalities; 3.5 (median; range 3-4 cores) targeted biopsies were performed in suspicious areas of peripher-

Figure 1.

Peripheral hypoechoic zone detected by TRUS (a).

Suspicious area of the peripheral parenchyma after Sonovue® administration during contrast-enhanced ultrasound (CEUS) continuous harmonic imaging evaluation (b).



al region in 16 (35.5%) and 6 (40%) patients at primary and repeated biopsy, respectively. In any case no areas of increased enhancement in any portion of the prostate was observed following Sonovue® administration.

In patients who underwent primary and repeated biopsy, PCa was detected in 20/45 (44.5%) and 3/15 (20%) cases; Sonovue® detected only 6/20 (30%) and 1/3 (33.4%) of these cancers, respectively. Moreover, histology identified in 15 (33.3%) and 6 (40%) men a normal parenchyma and in 10 (22.2%) and 6 (40%) a chronic prostatitis with median PSA equal to 9 ng/mL and positive DRE in 3 cases.

Clinical parameters of patients with PCa in both groups are listed in Table 1; median Gleason score and PSA were equal to 6.6 (range 6-10) vs 6.8 (range 6-9) and 15.1 ng/mL (range: 5-27) vs 9.8 ng/mL (range: 2.8-44 ng/mL) in men diagnosed by targeted and extended or SPBx, respectively. Based on analysis of biopsy positive core rate, the detection rate of SPBx vs directed CEUS biopsy was 16.7% (213 of 1275 cores) vs 19.5% (15 of 77 cores) ($p = 0.579$), respectively. Overall (60 patients) sensitivity and specificity of Sonovue®, DRE and TRUS in diagnosing PCa was equal to 30.4% and 59.4% vs 34.7% and 97.2% vs 39.1% and 51.4%, respectively; sensitivity and specificity of Sonovue® targeted cores at primary (45 patients) and repeated (15 patients) biopsy was equal to 30.0% and 61.5% vs 33.4% and 54.5%, respectively.

DISCUSSION AND CONCLUSIONS

The sextant prostate biopsy proposed by *Hodge et al.* (7) in 1989 was the golden standard in the diagnosis of PCa until it was demonstrated that about 15-20% of the clinically significant cancer were not diagnosed (8), with a consequent necessity of submitting many patients to several biopsy sets. Extended TRUS-guided prostate needle biopsy schemes with a increased number of cores on the peripheral portion and on the lateral margins of the gland constitute, nowadays, the only suitable method to increase the PCa diagnosis. *Beurton et al.* (9) using a biopsy schemes of 10-12 cores reported a 14% increase in detection rate of PCa at initial biopsy compared to the sextant biopsy set.

In case of repeated biopsy, SPBx (i.e., 24 or more cores) is recommended; in fact, SPBx does not improve cancer detection rate in comparison with 12-18 cores biopsy as an initial prostate biopsy strategy but significantly increases the diagnosis of PCa during a repeated biopsy (10). In our experience, at 2nd and 3rd biopsy, the detection rate for cancer was significantly higher using SPBx vs the 18 core scheme (22.6% vs 6.2% and 10.9% vs 0%) (10). On the other hand, SPBx increases the incidence of low volume PCa (a single positive core or a neoplastic microfocus) with the consequent risk of overdiagnosis/overtreatment of clinically insignificant PCa, (i.e., tumour less than 0.5 cc in volume without Gleason grade

Table 1.

Clinical parameters and PCa incidence at second and third biopsy.

Prostate biopsy	PSA ng/mL	DRE	TRUS	Sonovue®	Gleason score	Number of positive cores: saturation vs targeted biopsy
primary	3.4	neg	neg	neg	6 (3+3)	12/22 vs np
"	44	pos	pos	neg	10 (5+5)	18/18 vs np
"	23	neg	neg	neg	9 (5+4)	12/24 vs np
"	12	neg	neg	neg	7 (3+4)	1/22 vs np
"	6.9	neg	neg	neg	6 (3+3)	11/23 vs np
"	5.6	neg	neg	neg	6 (3+3)	2/23 vs np
"	15.5	pos	pos	pos	7 (3+4)	18/18 vs 3/3
"	3.2	pos	neg	neg	6 (3+3)	8/21 vs np
"	4.6	pos	neg	neg	6 (3+3)	2/18 vs np
"	27	pos	pos	pos	6 (3+3)	16/22 vs 3/4
"	5	neg	pos	pos	7 (3+4)	7/25 vs 1/3
"	8.7	neg	neg	neg	7 (3+4)	10/28 vs np
"	2.8	neg	neg	neg	6 (3+3)	1/25 vs np
"	6.1	neg	pos	pos	6 (3+3)	16/28 vs 1/3
"	13	neg	neg	neg	6 (3+3)	6/24 vs np
"	7.2	pos	pos	pos	6 (3+3)	9/18 vs 2/4
"	3.8	neg	neg	neg	6 (3+3)	2/18 vs np
"	4.3	neg	neg	neg	6 (3+3)	1/19 vs np
"	8.3	neg	neg	neg	6 (3+3)	4/18 vs np
"	5.2	neg	neg	neg	6 (3+3)	2/18 vs np
repeated	22	pos	pos	pos	7 (4+3)	8/25 vs 2/4
"	23	pos	pos	pos	9 (5+4)	24/24 vs 3/3
"	9	pos	pos	neg	8 (4+4)	23/28 vs np

DRE: digital rectal examination; TRUS: transrectal ultrasound; neg: negative; pos: positive; np: not performed.

4 or 5 disease) (11); moreover, SPBx increases the risk of biopsy-related complications and requires to be performed under sedation (10).

An ideal approach to the diagnosis of PCa should be to detect significant disease performing a limited number of targeted biopsy cores, especially in case of repeated biopsy.

With the aim to improve TRUS-guided prostate biopsy accuracy, a number of papers have been published on the use of UCA as an additional diagnostic tool for improving PCa detection (2-4).

Yi *et al.* (12) compared the diagnostic accuracy of TRUS, CDU and CECD (contrast-enhanced color Doppler) in 48 patients after Levovist® (galactose) i.v. injection: UCA administration increased only the sensitivity but not improved the specificity; similarly, in a previous study we observed a good sensitivity (88.8%) but a poor specificity (54.5%) in 34 patients submitted to Levovist® CECD targeted biopsy (13).

In the last years many studies revealed that CEUS targeted prostate biopsies significantly improved the positive biopsy core rate and the accuracy in detecting cancers with higher Gleason scores. Pelzer *et al.* (2) evaluated PCa detection rate performing targeted CECD biopsy vs systematic 10-core biopsy in 308 men with PSA range of 4.0-10 ng/mL (PSA F/T < 18%) and showed an incidence equal to 27.4% vs 27.6% with a significantly better positive core rate for targeted biopsy in comparison with systematic biopsy (32.6% vs 17.9%). Mitterberger *et al.* (14) reported a significantly higher detection rate of cancer in subjects submitted to CECD targeted biopsy (32%) following Sonovue® administration vs 10-cores scheme (26%). Colleselli *et al.* (15) reported in 345 men a higher detection rate for PCa after CECD targeted biopsy vs 10-core scheme in small glands (volume < 30 mL) and low PSA values; Mitterberger *et al.* (16) in 221 PCa showed that CECD targeted biopsy (Sonovue®) detected cancers with significantly higher Gleason scores compared to 10-core biopsy. In 301 patients, Halpern *et al.* (3) found PCa in 15.5% of the CECD (Imagent®) cores and in 10.4% of sextant cores showing a higher detection rate using intermittent harmonic imaging in comparison with continuous harmonic imaging; Linden *et al.* (17) in 60 patients who underwent 10-core biopsy vs directed biopsy (5 cores) with microflow imaging (flash replenishment technique) vs both techniques diagnosed PCa in 5, 2 and 11 men respectively, with a higher number of positive cores (13% vs 8.3%) in case of directed biopsy. Taymoorian *et al.* (18) in 95 patients who underwent repeat biopsy reported a sensitivity and specificity for PCa equal to 100% and 48% performing CEUS directed cores (Sonovue®) with a higher detection rate (24/30 patients) in comparison with octant biopsy scheme (8/30 patients). In our experience, no advantages were provided by CEUS targeted biopsy following UCA administration and Sonovue® was unable to detect any cancer eventually missed by extended biopsy or SPBx. In comparison with DRE and TRUS, Sonovue® showed a lower sensitivity and specificity; it is remarkable that a significant number of cancer were missed if we compare the detection rate for PCa of directed cores vs SPBx equal to 35% (7 patients) vs 100% (23 patients) ($p = 0.0001$), respectively. In our

series, the lower detection rate for PCa, in comparison with the above mentioned studies in which CECD targeted biopsy were performed, could be explained by the poor accuracy of negative contrast enhancement that, on the contrary, constitutes a pathognomonic pattern after Sonovue® administration in patients with others solid cancers (particularly, liver masses) (6).

In conclusion, although the limited number of our patients requires further contributions, the poor results in terms of accuracy do not recommend Sonovue® CEUS continuous HI targeted biopsy as a useful additional tool in diagnosing PCa. The extended biopsy schemes (12 or 18 cores) and SPBx still represent the routine procedures to be performed in case of initial and repeated biopsy as they provide a detection rate for PCa of 34-47% (9,19) and 23% (10), respectively. The promising results reported in literature (3, 14, 17) should be confirmed by randomized clinical trials with standardized procedures in order to assess the role of CEUS HI and CECD targeted biopsy in routine clinical practice (20).

REFERENCES

1. Bott SR, Henderson A, Halls JE, Montgomery BS, Laing R, Langley SE. Extensive transperineal template biopsies of prostate: modified technique and results. *Urology* 2006; 68:1037.
2. Pelzer A, Bectik J, Berger AP, et al. Prostate cancer detection in men with prostate specific antigen 4 to 10 ng/ml using a combined approach of contrast enhanced color Doppler targeted and systematic biopsy. *J Urol* 2005; 173:1926.
3. Halpern EJ, Ramey JR, Strup SE, et al. Detection of prostate carcinoma with contrast-enhanced sonography using intermittent harmonic imaging. *Cancer* 2005; 104:2373.
4. Heijmink SW, Barentsz JO. Contrast-enhanced versus systematic transrectal ultrasound-guided prostate cancer detection: an overview of techniques and systematic review. *Eur J Radiol* 2007; 63:310.
5. Aragona F, Pepe P, Motta M, et al. Incidence of prostate cancer in Sicily: results of a multicenter case-findings protocol *Eur Urol* 2005; 47:569.
6. Jang HJ, Kim TK, Wilson SR. Imaging of malignant liver masses: characterization and detection. *Ultrasound Q* 2006; 22:19.
7. Hodge KK, McNeal JE, Terris MK, Stamey TA. Random systematic versus directed ultrasound guided transrectal core biopsies of the prostate. *J Urol* 1989; 142:71.
8. Norberg M, Egevad L, Holberg L, Sparen P, Norlen BJ, Busch C. The sextant protocol for ultrasound-guided core biopsies of prostate underestimates the presence of cancer. *Urology* 1997; 50:562.
9. Beurton D, Izadifar V, Barthelemy Y, Desgrappes A, Fontaine E. 12 systematic prostate biopsies are superior to sextant biopsies for diagnosing carcinoma: a prospective randomised study. *Eur Urol* 2000; 37:296.
10. Pepe P, Aragona F. Saturation prostate needle biopsy and prostate cancer detection at initial and repeat evaluation. *Urology* 2007; 70:1131.
11. Epstein J, Walsh P, Carmichael M. Pathological and clinical findings to predict tumor extent of non palpable (stage T1c) prostate cancer. *JAMA* 1994; 271:368.
12. Yi I, Kim JK, Park SH, et al. Contrast-enhanced sonography for

prostate cancer detection in patients with indeterminate clinical findings. *AJR* 2006; 186:1431.

13. Pepe P, Panella P, Patanè D, Aragona F. Does the adjunct of echographic contrast medium Levovist improve the detection rate of prostate cancer? *Prostate Cancer and Prostatic Diseases* 2003; 6:159.

14. Mitterberger M, Horninger W, Pelzer A, et al. A prospective randomized trial comparing contrast-enhanced targeted versus systematic ultrasound guided biopsies: impact on prostate cancer detection. *Prostate* 2007; 67:1537.

15. Colleselli D, Bektic J, Schaefer G, et al. The influence of prostate volume on prostate cancer detection using a combined approach of contrast-enhanced ultrasonography-targeted and systematic gray-scale biopsy. *BJU Int* 2007; 100:1264.

16. Mitterberger M, Pingerra GM, Horninger W, et al. Comparison of contrast enhanced color Doppler targeted biopsy to conventional

systematic biopsy: impact on Gleason score. *J Urol* 2007; 178:464.

17. Linden RA, Trabulsi EJ, Forsberg F, et al. Contrast enhanced ultrasound flash replenishment method for directed prostate biopsies. *J Urol* 2007; 178:2354.

18. Taymoorian K, Thomas A, Slowinski T, et al. Transrectal broadband-Doppler sonography with intravenous contrast medium administration for prostate imaging and biopsy in men with elevated PSA value and previous negative biopsies. *Anticancer Res* 2007; 27:4315.

19. Pepe P, Aragona F. Prostate needle biopsy: 12 vs 18 cores. Is it necessary? *Urol Intern* 2005; 74:19.

20. Heijmink SW, Barentsz JO. Contrast-enhanced versus systematic transrectal ultrasound-guided prostate cancer detection: an overview of techniques and systematic review. *Eur J Radiol* 2007; 63:310.



Correspondence

Pietro Pepe, MD
Azienda Ospedaliera Cannizzaro
Divisione di Urologia
via Messina, 829 - 95126 Catania, Italy
piepepe@hotmail.com

Giuseppe Candiano, MD
Divisione di Urologia
Azienda Ospedaliera Cannizzaro
via Messina, 829 - 95126 Catania, Italy

Michele Pennisi, MD
Divisione di Urologia
Azienda Ospedaliera Cannizzaro
via Messina, 829 - 95126 Catania, Italy

Francesco Aragona, MD
Divisione di Urologia
Azienda Ospedaliera Cannizzaro
via Messina, 829 - 95126 Catania, Italy

Elasto-sonography of the testis: Preliminary experience.

Marco Grasso ¹, Salvatore Blanco ¹, Marco Raber ¹, Luca Nespoli ²

¹ Department of Urology;

² Department of Surgery, San Gerardo Hospital, University of Milano-Bicocca, Monza, Italy

Summary

Objectives: We report our experience in elastosonography, a new developed ultrasonographic diagnostic dynamic technique used to provide an estimation about tissue stiffness.

Methods: 41 patients who presented with scrotal pain, painless enlargement of the scrotum or testicular nodules and infertility were submitted to ultrasound examination (US), color doppler ultrasonography (CDU), elastosonography examination (E). During ultrasonography examination we obtained conventional B-mode images. Lesion size was defined by the major diameter. The color doppler examination was performed to evaluate the vascular pattern. Subsequently we obtained elasticity images, with the patient in supine position. We used Hi Vision™ 8500 (Hitachi-Tokyo, Japan) ultrasonography machine with SonoElastography imaging option and we scanned with 7,5 MHz linear probe. To obtain images that were appropriate for analysis, we applied the probe with only light pressure, which we defined as a level of pressure that maintained contact with the skin and permitted imaging conditions for which the association between pressure and strain was essentially proportional.

Results: In 38 cases elastosonography confirmed the US and CDU findings. In the remaining 3 cases it allowed a better characterization of 2 small benign tumors and of an intratesticular haematoma.

Conclusion: In our preliminary experience elastosonography can provide additional informations by an higher definition in those cases where there are solid testicular lesions smaller than 10 mm. Infact elastosonography resulted helpful in the determination of 2 small lesions diagnosed after surgery as Sertoli tumor and adenomatoid tumor of the testis, respectively in a third case the elastosonography identified an intraparenchymal hematoma (confirmed after surgical exploration) in the differential diagnosis with a solid tumor. Further systematic experience is needed for better characterization of testicular lesions with this newly developed technique.

KEY WORDS: Elasto-sonography; Testis; Ultrasound; Doppler.

Submitted 21 December 2009; Accepted 15 March 2010

INTRODUCTION

Elastosonography is a newly developed dynamic technique that uses ultrasound (US) to provide an estimation of tissue stiffness by measuring the degree of distortion under the application of an external force. The principle of elastosonography is that tissue compression produces strain (displacement) within the tissue and that the strain is smaller in harder tissue than in softer tissue. Therefore, by measuring the tissue strain induced by compression, we can estimate tissue hardness, which may be useful in diagnosing cancer. Malignant lesions are often associated with changes in the mechanical properties of tissue, and

US elastosonography has been used to differentiate cancers from benign lesions in prostate, breast, pancreas, and lymph nodes (1-8). Clinical application on testicular lesions has never been reported yet. We report our preliminary experience.

METHODS

We report our experience on testicular elastosonography, started on november 2008, concerning 41 patients who reported scrotal pain (20 patients), painless enlargement

of the scrotum or testicular nodules (13 patients) and infertility (8 patients).

All patients were submitted to ultrasound (US) and color doppler ultrasonography (CDU) supplemented by elastosonography examination (E).

During ultrasonography examination we obtained conventional B-mode images. Lesion size was defined by the major diameter. The color doppler examination was performed to evaluate the vascular pattern. Subsequently we obtained elasticity images, with the patient in supine position. We used Hi Vision™ 8500 (Hitachi-Tokyo, Japan) ultrasonography machine with SonoElastography imaging option and we scanned with 7,5 MHz linear probe. The probe was applied to the testis and was moved slightly upward and downward to obtain the elasticity images. To obtain images that were appropriate for analysis, we applied the probe with only light pressure, which we defined as a level of pressure that maintained contact with the skin and permitted imaging conditions for which the association between pressure and strain was essentially proportional. We avoided using higher levels of pressure, which show nonlinear properties of tissue elasticity; in such circumstances, the association between pressure and strain is no longer proportional. The level of pressure was indicated on the display and scored from 1 to 8. In order to maintain the proportion between pressure and strain, the level of probe pressure was maintained between 3 to 6.

RESULTS

We examined 41 patients (mean age $31 \pm 5,4$ years; range 17-68). In 38 cases elastosonography confirmed US and CDU findings. In two cases elastosonography allowed a better characterization of very small testicular tumors (Sertoli cell tumor and adenomatoid tumor). In the third case an intratesticular hematoma was demonstrated.

CASE 1: a 33 years old patient referred for infertility. No symptoms were referred and physical examination was negative. Ultrasonography incidentally hardly detected one small deep unclearly defined hypoechoic lesion in the left testicle. Color Doppler did not detect any vascular pattern. Elastosonography showed an homogeneous hard pattern. Inguinal surgical exploration detected a small hard nodule and Sertoli cell tumor was diagnosed. Tunica albuginea was sutured and the testicle was preserved.

CASE 2: a 38 years old patient referred after self examination of the left testis where a little solid lesion was palpable on the superior part adjacent the head of epididymis. Ultrasonography showed an hyperechoic area with acoustic shadow below (Figure 1). Color Doppler did not detect any peculiar vascular pattern.

Elastosonography showed an homogeneous hard pattern with clear and regular boundaries. Inguinal surgical exploration detected a nodule of the tunica albuginea (Figure 2) diagnosed as Adenomatoid tumor. Tunica albuginea was sutured and the testicle was preserved.

CASE 3: a 29 years old patient presented to our outpatient service for right testicular pain. Testicular trauma was ruled out and physical examination demonstrated an hardening of the lower pole of the right testicle. Ultrasonography

Figure 1.

Case 2: ultrasonography shows an hyperechoic area with acoustic shadow.

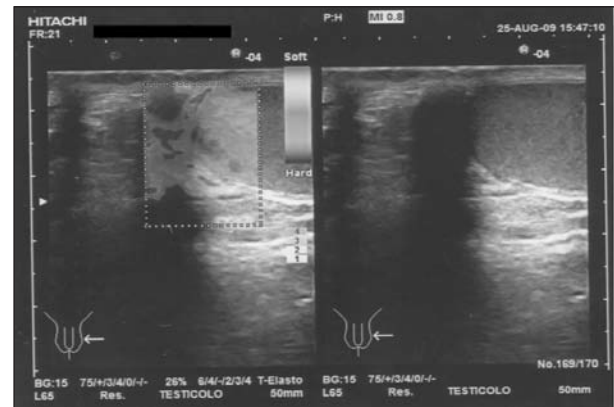


Figure 2.

Case 2: surgical exploration detects a nodule of the tunica albuginea.

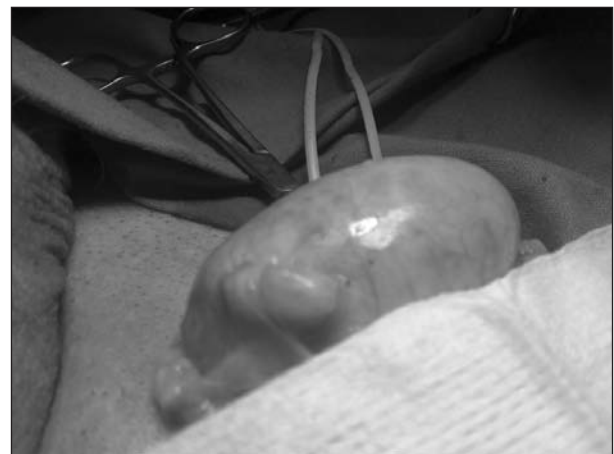

Figure 3.

Case 3: elastosonography shows a disomogeneous pattern with prevalence of low consistency.

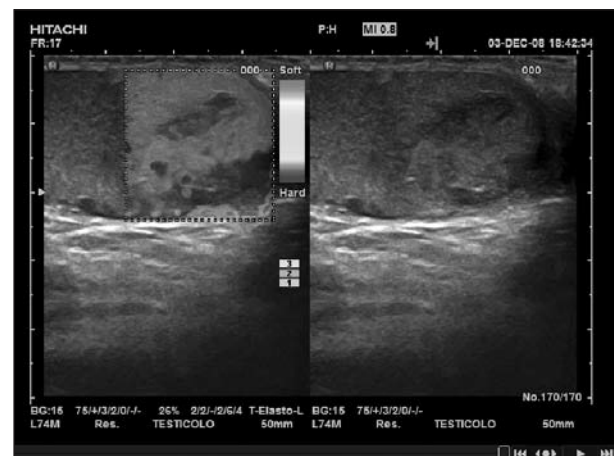
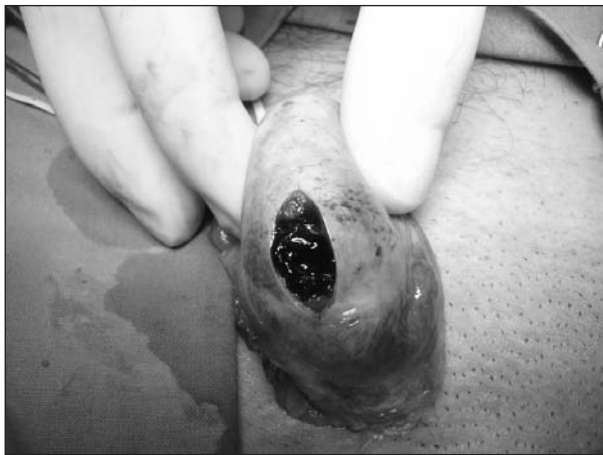
Figure 4.
Case 3: surgical exploration shows an hematoma.



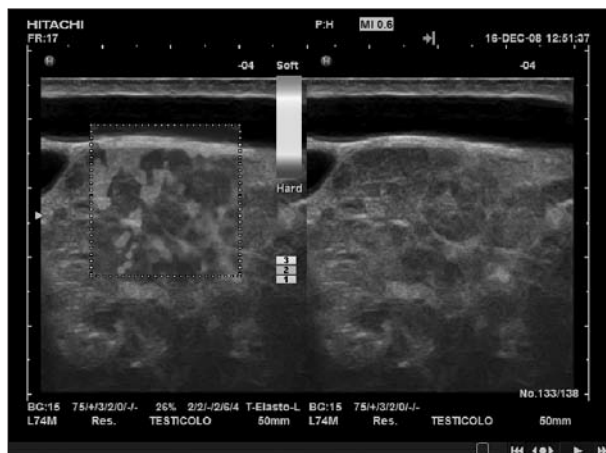
detected a disomogeneous area involving a significant part of the lower pole of the testicle. Color Doppler ultrasound detected no vascular flow inside the lesion. Elastosonography showed a disomogeneous pattern with prevalence of low consistency (Figure 3).

Tumor markers were negative. Inguinal surgical exploration showed a hematoma (Figure 4) and histological examination of tissue margins was negative for neoplasm. Tunica albuginea was sutured and the testicle was preserved.

DISCUSSION

Diagnosis and characterization of testis lesions are based on physical examination and ultrasonography. Physical examination based on the detection of changes in tissue stiffness or elasticity is an effective method to detect tissue abnormalities. However, palpation is related to the physician's sensibility as small and deep nodules might be

Figure 5.
Elastosonography of malignant and benign tumours is quite similar.



undetected even by an experienced physician. Even if ultrasonography easily detects these lesions, any further characterization about their consistency is almost impossible. In our opinion, elastosonography might be useful in such cases. This is indeed a dynamic technique that evaluates the degree of distortion of a tissue under application of an external force and is based on the principle that softer parts of tissues can deform more easily than harder parts under compression, thus allowing an objective determination of tissue consistency (9, 10).

In the third case diagnosis was difficult because of the relative hardening of the lesion due to the strain caused by the thickness of the hematoma. Even the ultrasonography was not definitive in ruling out a malignant tumor. Elastosonography, however, did not show any clear and certain hardening inside lesion or in the adjacent parenchyma. We found, in our preliminary experience, this newly developed technique very helpful in differentiating tumors due to hematoma of the testis from malignant lesions.

Hematoma indeed is characterized by a disomogeneous elastosonographic pattern composed by parts with very low consistency and other parts of the same lesion that appear harder. This image is quite different from tumor characterized by homogeneous hardening of the lesion. Unfortunately we were not able to differentiate malignant and benign tumors on the base of elastosonography because the pattern was quite similar (Figure 5).

Indeed the small lesion of the first and second case could have been referred to an early malignant tumor incidentally diagnosed. Anyway, surgical examination is mandatory in both cases.

For these reasons in our opinion the differentiation between malignant and benign lesions based on elastosonography is questionable while hematoma may be easily differentiated. However, when physical examination and ultrasonography are not helpful in the characterization of testicular lesions, elastosonography cannot be considered alone in differentiating a lesion that can be followed up like as hematoma. History of trauma, testicular pain and tumor markers help selecting those lesions that can be followed up over time. If any doubt exists surgical exploration is always advisable.

Systematic examination of tumor lesions of the testis is needed in order to correlate a specific hardening pattern to malignant or benign tumor.

CONCLUSION

Elastosonography may be an useful test to differentiate testicular lesions that may be followed over time from those in which surgical exploration is mandatory. However, it cannot be considered discriminating without other diagnostic steps such as physical examination, ultrasonography, careful history and tumor markers. Further systematic experience is needed for better characterization of testicular lesions with this newly developed technique.

REFERENCES

1. Garra BS, Cespedes EI, Ophir J, et al. Elastography of breast lesions: initial clinical results. *Radiology* 1997; 202:79-86.

2. Cochlin DL, Ganatra RH, Griffiths DE. Elastography in the detection of prostatic cancer. *Clin Radiol* 2002; 57:1014-1020.
3. Lyshchik A, Higashi T, Asato R, et al. Thyroid gland tumor diagnosis at US elastography. *Radiology* 2005; 237:202-211.
4. Thomas A, Fischer T, Frey H, et al. Real-time elastography an advanced method of ultrasound: first results in 108 patients with breast lesions. *Ultrasound Obstet Gynecol* 2006; 28:335-340.
5. Miyanaga N, Akaza H, Yamakawa M, et al. Tissue elasticity imaging for diagnosis of prostate cancer: a preliminary report. *Int J Urol* 2006; 13:1514-1518.
6. Yamakawa M, Nitta N, Shiina T, et al. High-speed freehand tissue elasticity imaging for breast diagnosis. *Jpn J Appl Phys* 2003; 42:3265-3270.
7. Lyshchik A, Higashi T, Asato R, et al. Cervical lymph node metastases: diagnosis at sonoelastography-initial experience. *Radiology* 2007; 243:258-267.
8. Giovannini M, Hookey LC, Bories E, et al. Endoscopic ultrasound elastography: the first step towards virtual biopsy? Preliminary results in 49 patients. *Endoscopy* 2006; 38:344-348.
9. Lerner RM, Huang SR, Parker KJ. "Sonoelasticity" images derived from ultrasound signals in mechanically vibrated tissues. *Ultrasound Med Biol* 1990; 16:231-239.
10. Ophir J, Alam SK, Garra B, et al. Elastography: ultrasonic estimation and imaging of the elastic properties of tissues. *Proc Inst Mech Engh H* 1999; 213:203-233.



Correspondence

Marco Grasso, MD
Department of Urology,
San Gerardo Hospital,
University of Milano-Bicocca,
Monza, Italy
m.grasso@hsgerardo.org

Salvatore Blanco, MD
Department of Urology,
San Gerardo Hospital,
University of Milano-Bicocca,
Monza, Italy

Marco Raber, MD
Department of Urology,
San Gerardo Hospital,
University of Milano-Bicocca,
Monza, Italy

Luca Nespoli, MD
Dept Surgery
Department of Urology,
San Gerardo Hospital,
University of Milano-Bicocca,
Monza, Italy

Corporoplasty by plication: Out patient surgery for the correction of penile curvature.

Mauro Seveso, Gianluigi Taverna, Guido Giusti, Alessio Benetti, Orazio Maugeri, Alessandro Piccinelli, Pierpaolo Graziotti

Istituto Clinico Humanitas, Unità Operativa di Urologia, Rozzano (MI), Italy

Summary

Objective: Corporoplasty using plication of the albuginea is a simple technique but considered by many Authors at high risk for recurrence in respect to other corrective techniques using excision of the albuginea tunica. The aim of this study was to assess long term functional and cosmetic results of this approach done in an outpatient environment.

Material and methods: From January 1997 to December 2008 we submitted 217 patients presenting induratio penis plastica (183) or congenital curvature (34) to corporoplasty with albuginea plication. All patients were assessed preoperatively with history, physical examination and photographic documentation of the erectile penis. These patients, all with vaginal penetration problems, were submitted to corporoplication with 2-4 sutures 2/0 (polyglycolic) contralateral to the curvature, using local anaesthesia on outpatient basis. Follow-up included functional and cosmetic results, eventual complications and level of patient satisfaction.

Results: Median follow-up of our study was 44 months (range 2-58). Complete correction of curvature was achieved in 206 patients (95%) whereas 87% reported good erectile function (IIEF-5 > 21). 145 patients (67%) reported penis shortening and 41% complained of palpating the sutures. Two patients required reoperation for recurring curvature. No perioperative complications or altered sensitivity of the glans were reported.

Conclusions: Simple plication of the corpora cavernosa can be done on an outpatient basis using local anaesthesia with optimal functional and cosmetic results. The success of this minimally invasive approach makes it a valid alternative to standard excision of the tunica albuginea procedure. Detailed preoperative information concerning procedure expectations and treatment course are extremely important in obtaining complete functional and cosmetic patient satisfaction.

KEY WORDS: Penile curvature, Corporoplasty, Outpatient surgery.

Submitted 19 February 2009; Accepted 30 June 2009

INTRODUCTION

Penile curvature is a malformation on the increase in urologic ambulatory practice. The curvature may be congenital but in most cases the cause is Peyronie's disease. This disease is characterized by fibrotic plaques of the penile tunica albuginea, which may initially cause painful erections followed by curvature of the penile shaft and difficulty or impossibility to penetrate, leading to erectile dysfunction of the cavernous bodies both for psychological reasons as well as for haemodynamic alteration. It is estimated that 3.2% of Caucasian males have Peyronie's disease, with a prevalence of patients between the ages of 40 and 70 years (1, 2).

Several methods of treatment have been proposed: medical treatment using oral administration of vitamin E, tocopherol with antioxidant properties, or local injections

of beta-antagonists such as steroids or verapamil, extracorporeal shockwave therapy (ESWT) of the plaques and finally the surgical approach. The altered morphology of the penis can in fact be corrected by excising the plaques and placing non-autologous or venous implants, intracavernous prosthesis or plication of the tunica albuginea contralateral to the site of maximum penile curvature (3, 4). Thought by many Authors to be at high risk for recurrence, plication is however a simple to perform technique, that does not require opening the cavernous bodies or mobilisation of the neurovascular bundles with a low complication rate and minimal risk of over-correction (5-7). The aim of our study is to evaluate long term functional and cosmetic results of this procedure carried out using local anaesthetic on an outpatient basis.

MATERIALS AND METHODS

From January 1997 to December 2008, 217 patients aged between 19 and 74 years underwent plication of the cavernous bodies. Thirty-four patients had congenital penile incurvature whereas 193 had Peyronie's disease. All patients reported impossibility or great difficulty in penetration with loss of the erectile state.

Before being submitted to surgery, the patients must have had the disease for at least one year, present a stable curvature for at least 6 months and be without pain.

Patients were assessed preoperatively with history, physical examination and photographic documentation of the erect penis with dorsal and lateral view of the shaft.

One hundred and eighteen patients (55%) presented a left deviation, 26 (12%) a right deviation, 47 (21%) ventral and 26 (12%) dorsal. None of the patients had undergone previous corrective surgery or shockwave treatment for the curvature, whereas the majority with Peyronie's disease had been pretreated with Vitamin E.

Surgical technique: the patient was carefully informed preoperatively about indications to surgical correction, risks of post-operative penile shortening and suture palpation, possible complications and realistic efficacy of the procedure. The patient was also given an informed consent form explaining technical method and possible complications, as well as suggestions for postoperative management.

Surgery was carried out using local anaesthesia on an outpatient basis. After positioning the patient on the operating table, the genital area was washed thoroughly and an antiseptic tincture applied. Using local anaesthesia with dorsal nerve and peripenile block using lidocaine and administering antibiotic iv (cephalosporin), a subcoronal circumcising incision was performed to deglove the entire penile shaft. A tourniquet was placed at the base of the penis and erection was induced by injecting a saline solution into the corpora cavernosum through a 19 G butterfly needle positioned laterally. Once an optimal artificial erection and exposure of the tunica albuginea was achieved, curvature grade and position was assessed and one or more pairs of sutures in polyglyconate monofilament 2/0 were placed at the edge point of major convexity of the penile shaft with introflexing knots according to the modified Essed-Schroeder technique. The number of sutures placed was established on achieving penile straightening. All the members of the surgical team are asked to assess results. Corrections can be made by loosening the suture or adding new sutures. The overhanging Buck's fascia is then closed with continuous polyglyconate suture and the skin is sutured with detached stitches in absorbable material. A lightly compressive bandage to be changed daily is then put on the area. Patients are kept under observation for 3 hours to check that the bandage is not too tight. They are then discharged with indication for anti-inflammatory treatment for 7 days, abstinence from sexual intercourse for 2 months and check up after 7 days, 3 and 6 months and then once yearly. During follow up we assessed functional and cosmetic results, eventual complications and level of patient satisfaction.

RESULTS

Mean operating time was 51 minutes. No peri-operative complications were reported. All patients were dis-

charged to home on the same day of their procedure and none required new admission in the immediate post-operative period (30 days).

Mean follow-up was 4 years (range 3-106 months).

Curvature correction making sexual intercourse without pain or penetration difficulties was achieved in 206 patients (95%), whereas complete curvature correction was recorded in 86%. 188 patients (87%) maintained on long term follow-up a good erectile function without need for therapeutic treatment with prostaglandin or phosphodiesterase type 5 inhibitors. No over-corrections were recorded. 145 patients (67%) reported penile shortening, which did not, however, determine any interference in sexual intercourse.

– **Complications:** in the peri-operative period a haematoma was recorded which was treated conservatively and one case of residual prepuce flap necrosis which required minimal surgical intervention. Six months from surgery, two patients underwent new correction by means of corporoplasty according to Nesbit for recurring curvature, which lead to complete resolution. One patient required surgical revision for the formation of a granuloma 5 months after primary procedure. The most common patient complaint at long term follow-up, reported by 30 patients (14%), was a palpable suture. There were no cases of disease progression in patients affected by Peyronie's disease. 19 patients (9%) reported a minimal change in glans sensitivity.

DISCUSSION

Bayley *et al.* demonstrated that 10% of patients affected by Peyronie's disease require surgical correction but the most adequate therapeutic approach remains unclear (7). Most Authors however, perform corrective surgery under general or loco-regional anaesthesia (8, 9).

In patients presenting congenital penile curvature or Peyronie's disease not associated with erectile dysfunction, we propose a minimally invasive approach. Tunica albuginea plication with inverted knots under local anaesthesia on an outpatient basis, has a high functional and cosmetic success rate associated with minimum morbidity. We adopt the albuginea plication technique only after the patient has consented to a reduction in penile length. We believe it is imperative to have a straight discussion preoperatively into the realistic aims of treatment with both members of the couple. The aims of surgery are strictly limited to straightening the penis so as to make sexual intercourse possible and satisfactory (10, 11).

Based on preoperative diagnostics we believe the use of colour-Doppler ultrasound to study penile haemodynamics should be limited to those cases of doubtful erectile validity (12-14).

None of the patients required analgesedation during the operation and all, after a brief observation period, were discharged on the same day with precise indications on medication to be done at home, two months abstinence from sexual intercourse and necessity for continuous outpatient monitoring. This is crucial for a correct evaluation of therapeutic success, to avoid complications such as the feared wound infections and as to psychologically sup-

port to the patients, so as to avoid unrealistic expectations or disappointment in treatment results (14).

It is our belief that as well as detailed preoperative information regarding the risks of penis shortening and scar palpability, continuous, long term assistance is also necessary. Palpability of the sutures was reduced over time by the use of absorbable suture which have substituted the non-absorbable suture (polypropylene) used during our first years' experience (15).

Post-operative penile shortening was recorded in 67% of our patients but in no case did this cause erectile disturbances of a psychological nature or determine a negative assessment of the operation or therapeutic choice.

The original plication of the tunica albuginea technique proposed by Essed and Schroeder, involved mobilisation of the urethra and neurovascular bundle. Over the course of time this has been modified making the technique much easier and less invasive, avoiding dissection of both the urethra and neurovascular bundles and the consequent erectile complications (16, 17). It must be stressed that the constant intraoperative control when making plication suture and the tension applied, enables the surgeon to evaluate straightness achieved with a lack of over-correction (18).

The risk of postoperative complications such as haematoma, wound infection, can be reduced with careful respect of the basic principles of surgical asepsis and post-operative follow-up. It is essential to keep the wound clean and medicate with a lightly compressive dressing not completely covering the penis for at least 10 days. No therapeutic advantage was noted by administering a protracted antibiotic therapy for longer than the peri-operative phase (19). Our results confirm those already described in the literature, adding and underlining the minimally invasive nature of this technically simple and quick to perform procedure, which has minimal patient impact and can be carried out with local anaesthesia on an outpatient basis. We therefore propose this approach to all patients with penile curvature congenital or secondary to Peyronie's disease with spared erectile activity.

REFERENCES

1. Scharzer U, Sommer F, Klotz T, Braun M, Reinfenrath B, Engelmann U. The prevalence of Peyronie's disease: result of a large survey. *BJU Int* 2001; 88:727-30.
2. Gelbard MK, Dorey F, James K. The natural history of Peyronie's disease. *J Urol* 1990; 144:1376-9.
3. Savoca G, Scioeri F, Pietropaolo F, Garaffa G, Belgrano E. Straightening corporoplasty for Peyronie's disease: a review of 218 patients with median follow up of 89 months. *Eur Urol* 2004; 46:610-614.
4. Tornehl C, Carson C. Surgical alternatives for treating Peyronie's disease. *BJU International* 2004; 94:774-78.
5. Geersten UA, Brok KE, Andersen B, Nielsen HV. Peyronie curvature treated by plication of the penile fasciae. *BJU* 1996; 77:733-735.
6. Daitch J, Angermeier KW, Montague D. Modified corporoplasty for penile curvature: long term results and patient satisfaction. *J Urol* 1999; 162:2006-2009.
7. Bailey MJ, Yande S, Walmsley B. Surgery of Peyronie's disease. *Br J Urol* 1985; 57:746-9.

8. Giammusso B, Burello M, Branchina A, Nicolosi F, Motta M. Modified corporoplasty for ventral penile curvature: description of the technique and initial results. *J Urol* 2004; 171:1209-1211.

9. Hsieh JT, Liu SP, Chen Y, Chang H, Chen CH. Correction of congenital penile curvature using modified tunical plication with absorbable sutures: the long term outcome and patient satisfaction. *Eur Urol* 2007; 52:261-267.

10. Friedrich MG, Evans D, Noldus J, Huland H. The correction of penile curvature with the Essed-Schroeder technique: a long-term follow-up assessing functional aspects and quality of life. *BJU International* 2000; 86:1034-1038.

11. Hsu GL, Chen SH, Weng SS. Out patient surgery for the correction of penile curvature. *BJU* 1997; 79:36-39.

12. Chien G, Abouseif S. Corporeal plication for the treatment of congenital penile curvature. *J Urol* 2003; 169:599-602.

13. Van Der Horst C, Martinez Portillo F, Alken P, Seif C, Juenemann KP. Treatment of penile curvature with Essed-Schroeder tunical plication: aspects of quality of life from the patients? *Perspective. BJU International* 2004; 93:105-108.

14. Yurkamin JP, Dean R, Wessels H. Effect of incision and saphenous vein grafting for Peyronie's disease on penile length and sexual satisfaction. *J Urol* 2001; 166:1796-72.

15. Carson C. Penile prosthesis implantation in the treatment of Peyronie's disease. *Int J Impotence Res* 1988; 10:125-8.

16. Backhaus BO, Muller SC, Albers P. Corporoplasty for advanced Peyronie's disease using venous and/or dermis grafting, new surgical technique and long term patient satisfaction. *J Urol* 2003; 169:981-4.

17. Van Der Horst C, Martinez Portillo F, Alken P, Juenemann KP. Polytetrafluoroethylene versus polypropylene sutures for Essed-Schroeder tunical plication. *J Urol* 2003; 170:472-475.

18. Gholami SS, Lue TF. Correction of penile curvature using the 16-dot plication technique: a review of 132 patients. *J Urol* 2002; 167:2066-9.

19. Devine CJ, Horton CE. Surgical treatment of Peyronie's disease with a dermal graft. *J Urol* 1974; 111:44-9.

Correspondence

Mauro Seveso, MD

Istituto Clinico Humanitas, Unità Operativa di Urologia
Via Manzoni 56 - 20089 Rozzano, Milano, Italy
mauro.seveso@libero.it

Gianluigi Taverna, MD

Unità Operativa di Urologia, Istituto Clinico Humanitas
Via Manzoni 56 - 20089 Rozzano, Milano, Italy

Guido Giusti, MD

Unità Operativa di Urologia, Istituto Clinico Humanitas
Via Manzoni 56 - 20089 Rozzano, Milano, Italy

Alessio Benetti, MD

Unità Operativa di Urologia, Istituto Clinico Humanitas
Via Manzoni 56 - 20089 Rozzano, Milano, Italy

Orazio Maugeri, MD

Unità Operativa di Urologia, Istituto Clinico Humanitas
Via Manzoni 56 - 20089 Rozzano, Milano, Italy

Alessandro Piccinelli, MD

Unità Operativa di Urologia, Istituto Clinico Humanitas
Via Manzoni 56 - 20089 Rozzano, Milano, Italy

Pierpaolo Graziotti, MD

Unità Operativa di Urologia, Istituto Clinico Humanitas
Via Manzoni 56 - 20089 Rozzano, Milano, Italy

Effect of aging on urinary incontinence in woman.

Carlo Vecchioli-Scaldazza¹, Carolina Morosetti²

¹ Division of Urology, Jesi Hospital, Jesi, Italy;

² Clinical Research, Jesi Hospital, Jesi, Italy

Summary

Objective: The aim of the study was to evaluate, in a group of female patients with urinary incontinence (UI), the effect of aging on: a) urodynamic findings; b) incidence of detrusor overactivity; c) types of urinary incontinence; d) pelvic organ prolapse; e) body mass index; f) anorectal disorders.

Material and Methods: Eighty four consecutive patients with urinary incontinence were enrolled in this study. Patients were divided into two groups according to their age: group A: patients with age ≤ 65 years, group B: patients with age > 65 years.

Patients underwent a full urogynaecological workup with a clinical evaluation and urodynamic study.

Results: In older patients urge and mixed urinary incontinence were the most prevalent type of (UI). In these patients an increase of the bladder sensation with a decrease of the bladder capacity, an increase of detrusor overactivity and a reduction of the maximum urethral closure pressure were found. Furthermore, a higher body mass index was observed in older patients.

Conclusions: The results of this study show an age-associated correlation of types of urinary incontinence, urodynamic findings, body mass index and incidence of detrusor overactivity.

KEY WORDS: Female urinary incontinence; Urodynamic study; Aging; Prolapse.

Submitted 14 February 2010; Accepted 15 March 2010

INTRODUCTION

Urinary incontinence (UI) is an important health problem affecting 10-55% of women during their lifetimes. The broad percentage variation depends on the study methods adopted and in particular patient age with significant increases in women aged over 60 (1-6). UI is associated with significant decrements in function and quality of life (7, 8). In US urinary incontinence-related costs are estimated about 20-26.3 billion dollars annually in societal costs (1-9) (nursing home admissions, loss of productivity, treatment, routine care, diagnostic studies). More than 8 billion dollars are spent annually for incontinence devices, which is more than for hemodialysis and coronary artery bypass surgery combined (10). The aim of this study was to evaluate, in a group of female patients with urinary incontinence, the effect of aging on:

- a) urodynamic findings;
- b) incidence of detrusor overactivity (DO);
- c) types of urinary incontinence;
- d) pelvic organ prolapse;
- e) body mass index (BMI);
- f) anorectal disorders.

MATERIALS AND METHODS

Between January and September 2009, 120 consecutive female patients complaining of urinary incontinence were enrolled in this study. Of these, 36 were excluded after clinical evaluation.

Exclusion criteria: patients with neurological disease, diabetes mellitus, current urinary tract infection, history of irradiation and/or surgical treatment and/or tumor of pelvic organs, were excluded.

Patients were divided into two groups according to their age: group A: patients with age ≤ 65 years (46), group B: patients with age > 65 years (38).

All women underwent a full urogynaecological workup which included detailed history, a 3-day bladder diary, body mass index calculation (calculated as weight in kilograms divided by the square of height in meters), clinical examination with assessment of vaginal profile according to *Baden and Walker* (11) with the patient in the lithotomy position and maximum straining effort and a complete urodynamic evaluation.

The study comprised uroflowmetry with determination of post void residual volume (PVR), conventional filling cystometry performed using a 6 Fr. double-lumen

transurethral catheter with patient in the sitting position. In this case the bladder was filled with normal saline at room temperature at a rate of 30 ml/min with rectal pressure monitoring. Bladder filling was discontinued when patient could no longer delay micturition and subsequently women were asked to void with the transurethral catheter in place.

Afterwards, urethral pressure profile at rest and during increase of intra-abdominal pressure was performed.

Maximum and average flow rate (Q_{max} and Q_{ave}), flow time, PVR performed by catheterisation and voided volume on uroflowmetry; maximum urethral closure pressure (MUCP) and functional profile length (UL) on urethral pressure profile; first sensation of bladder filling (FS), first desire to void (FD), strong desire to void (SD), maximum cystometric capacity (MCC) on cystometry; detrusor

pressure at the onset of urine flow (pdet.open), detrusor pressure at maximum flow (pdet.Q_{max}), maximum detrusor pressure (pdet.max) in pressure-flow study were recorded. Detrusor overactivity (DO) was defined as the occurrence of an involuntary detrusor contraction during filling phase, either spontaneous or provoked (12).

Urodynamic investigation was performed using Urobenchmark 2000/P (SIEM.)

Statistical analysis: statistical analysis was done using Mann-Whitney test for independent samples for quantitative variables, whereas the hypothesis about a difference in proportions was tested using Pearson's chi square test. A p value of less than 0.05 was considered statistically significant. Methods, definitions and units conform to the standards recommended by the International Continence Society (12-14).

Table 1.
Types of urinary incontinence.

Urinary incontinence	Group A (age ≤ 65) n. patients	Group B (age > 65) n. patients	p value
Stress incontinence	30	8	p = 0.0003
Stress + urge incontinence	11	21	
Urge incontinence	5	9	

Table 2.
Pelvic organ prolapse: Prolapse degree according to halfway system.

Vaginal prolapse degree	Group A (age ≤ 65) n. patients	Group B (age > 65) n. patients	p value
Degree 0	3	9	p = 0.0626
Degree 1	41	23	
Degree 2	19	17	
Degree 3	1	0	
Degree 4	0	0	

Table 3.
Pelvic organ prolapse: prolapsed vaginal segment.

Vaginal segment	Group A (age ≤ 65) n. patients	Group B (age > 65) n. patients	p value
Anterior wall	34	20	p = 0.8758
Medial segment	8	4	
Posterior wall	8	6	

Table 4.
Body mass index (Mean ± standard deviation).

	Group A (age ≤ 65)	Group B (age > 65)	p value
Body mass index	23.93 ± 3.51	28.88 ± 2.68	p = 0.0001

Table 5.
Anorectal disorders.

Anorectal disorders	Group A (age ≤ 65) n. patients	Group B (age > 65) n. patients	p value
Normal defecation	24	14	p = 0.2407
Constipation in IBS*	5	3	
Costipation	13	19	
Fecal incontinence	5	9	

* IBS: Irritable bowel syndrome

Table 6.
Urodynamic parameters (Mean ± standard deviation).

Urodynamic parameters	Group A (age ≤ 65)	Group B (age > 65)	p value
Q _{max} (mL/s)	26 ± 13	24 ± 14	p = 0.3664
Q _{ave} (mL/s)	16 ± 9	14 ± 9	p = 0.2302
Flow time (s)	24 ± 13	26 ± 16	p = 0.8257
PVR (mL)	32 ± 39	39 ± 57	p = 0.6467
Voided volume (mL)	299 ± 125	265 ± 117	p = 0.1806
MUCP (cmH2O)	68 ± 22	47 ± 16	p < 0.0001
UL (mm)	32 ± 6	30 ± 5	p = 0.4396
FS (mL)	219 ± 85	180 ± 71	p = 0.0249
FD (mL)	307 ± 106	256 ± 84	p = 0.0274
SD (mL)	415 ± 123	328 ± 99	p = 0.0013
MCC (mL)	472 ± 140	402 ± 134	p = 0.0183
Pdet. open (cmH2O)	26 ± 19	25 ± 12	p = 0.8468
Pdet. Q _{max} (cmH2O)	28 ± 19	25 ± 12	p = 0.7361
Pdet. max (cmH2O)	42 ± 19	37 ± 14	p = 0.2216

Table 7.
Overactive bladder.

Overactive bladder	Group A (age ≤ 65) n. patients	Group B (age > 65) n. patients	p value
Yes	5	11	p = 0.0357
No	41	27	

RESULTS

Mean patient age in group A was 53.7 years (range 30-65), and in group B was 75.4 years (range 66-87).

Stress incontinence was the most common type of urinary incontinence in younger women whereas urge and mixed incontinence were more frequently found in older patients (p = 0.0003) (Table 1).

No statistically significant difference was found in pelvic organ prolapse in group A and B both for the degree of prolapse (Table 2), and for the prolapsed vaginal segment

(Table 3). A higher body mass index was significantly associated with older patients with mean values of 28.88 versus 23.93 respectively (p < 0.0001) (Table 4).

Anorectal disorders (Table 5) did not show a statistically significant difference in the two groups of patients. A normal defecation was more common in women ≤ 65 years whereas constipation was the prevalent disorder in both groups of patients.

In the urodynamic study (Table 6), no statistically signif-

icant difference was found in uroflowmetry parameters even if Qmax and Qave were lower in older patients, and flow time and PVR were higher in these patients.

MUCP showed a statistically significant decrease with age, with a mean value of 47.29 in group B and a mean value in the youngest women (group A) of 68.20 ($p < 0.0001$). UL in older patients was lower but no significant difference was found. Bladder sensation and bladder capacity during filling cystometry diminished significantly with age with a FS, FD, SD and MCC with a p value = 0.0249, 0.0274, 0.0013, 0.0183 respectively. Furthermore a significant increase of the incidence of DO with age was found ($p = 0.0357$) (Table 7).

No statistically significant difference was found in the detrusor pressure in pressure – flow study, even if the mean value of the detrusor pressures in group B was always lower.

DISCUSSION

The data from the current study reveal age-associated differences in women with urinary incontinence. In agreement with authors (3, 5, 15-17) stress UI was the most prevalent type of UI, decreasing with age, whereas urge and mixed incontinence were the most prevalent type in patients over 65 years.

However, patients with overactive bladder syndrome, did not always demonstrate DO in the urodynamic study. Only 11 women out of 30, in group B, and 5 out of 16 in group A, with the symptoms of urge or mixed UI, showed a DO on the filling cystometry, confirming that the symptom itself was poorly associated with objective parameters.

In 2004 Brummen *et al.* (18) showed that the association between the urgency symptom and objective parameters is mainly the effect of concurrent frequency symptoms.

Amundsen *et al.* (2) reported that urinary symptoms do not correlate with urodynamic findings and subjective complaints were not helpful in differentiating the aetiology of urinary incontinence.

Urinary symptoms reported in a postal questionnaire were able to predict urodynamic diagnoses with moderate accuracy also in the experience of Matharu *et al.* (19). The filling phase of the cystometry in our study, revealed the presence of a premature first sensation, first desire and strong desire with decrease of the bladder capacity in older patients consistent with other experiences (10,20) but as underlined by Pfisterer *et al.* (21) and demonstrated by Long-Yau Lin *et al.* (22), the reduced bladder capacity with age may be related to the increase of DO rather than to aging itself (21).

We believe that this is a consideration that should be taken into account in the determination of the bladder capacity in elderly patients.

Indeed, our study showed that 11 out of 38 women with age > 65 had DO whereas only 5 out of 46 with age ≤ 65 had DO.

DO is common in the elderly. Changes in the structural features of the detrusor (muscle cells, interstitium and nerves) were found by electron microscopy (23), but a disturbed central neuronal control of the lower urinary tract (24), changes in the receptor profile with partial

cholinergic denervation of the detrusor with a subsequent upregulation of muscarinic receptor sensitivity (25) can explain the increase of DO in the elderly.

Urethral sphincter function declines with aging with a highly significant decrease of the MUCP. This finding, indicating a decrease in outflow resistance, is consistent with other studies (10, 21, 26) and is in relation to the structural and functional changes of the urethra. Urogenital atrophy in postmenopausal or castrated women is common and the effects of age and estrogen deprivation are practically inseparable (27).

The lack of estrogen affects the urinary tract mainly by diminishing vascular, muscular and epithelial trophism (28). In small specimens of periurethral connective tissue taken from stress-incontinent postmenopausal women with hypotonic urethra, Goepel and Thomssen (29) detected irregular fragmented distribution of the elastin within the tissue; these structural changes lead to functional consequences, such as diminished tissue extensibility and loss of stability surrounding the female urethra, whereas hormone therapy (estrogen and progesterone) has a positive effect on the urethral tissue increasing the number of periurethral vessels (28) and the urethral pressure on urodynamic study (30).

No statistical difference was found in pelvic organ prolapse both in degree and in the vaginal segment.

In most cases, the presence of first and second degree prolapses, can easily be explained by the fact that all patients in the study were incontinent and this symptom is in most cases associated with low degree prolapses, whereas high degree prolapses (III-IV) are more often associated with voiding symptoms (slow or intermittent stream, hesitancy, straining, terminal dribble).

In our study a higher body mass index (BMI) was significantly associated with older patients.

In literature the risk of urinary incontinence increases with BMI, but no relation was found between BMI and a specific type of UI (31-34).

Constipation was the prevalent anorectal disorder in both groups of patients (37%) whereas a low percentage of women with fecal incontinence was found (7%).

Some authors describe, in incontinent women with pelvic organ prolapse, a high prevalence of constipation (35) whereas other authors describe a high rate of fecal incontinence (36, 37). In our experience we found a low percentage of fecal incontinence, probably due to the presence in this study, of a limited number of patients with a severe rectocele.

CONCLUSIONS

This study shows age related differences in patients ≤ or > 65 years. In older patients urge and mixed UI were the most prevalent type of UI; furthermore in these patients an increase of the bladder sensation with a decrease of the bladder capacity, an increase of the incidence of DO and a highly significant reduction of the MUCP were found in the urodynamic study.

A higher BMI was associated with older patients.

No significant difference was found for anorectal disorders and pelvic organs prolapse.

REFERENCES

1. Gibbs CF, Johnson TM, Ouslander JG. Office Management of geriatric urinary incontinence. *Am J Med* 2007; 120:211.
2. Amundsen C, Lau M, English SF, et al. Do urinary symptoms correlate with urodynamic findings? *J Urol* 1999; 161:1871.
3. Hunskaar S, Lose G, Sykes D, et al. The prevalence of urinary incontinence in women in four european countries. *BJU International* 2004; 93:324.
4. Fanti JA, Newman DK, Colling J, et al. Urinary Incontinence in adults: acute and chronic management. Rockville, Md: US Dept of health and human services. Agency for health care policy and research; 1996. Clinical Practice Guideline 2.
5. Schumacher S. Epidemiology and etiology of urinary incontinence in the elderly. *Urologe A* 2007; 46:357.
6. Milsom I. The prevalence of urinary incontinence. *Acta Obstet Gynecol Scand* 2000; 79:1056.
7. Patrick DL, Martin ML, Bushnell DM, et al. Quality of life of women with urinary incontinence: further development of the incontinence Quality of Life Instrument (I-QOL). *Urology* 1999; 53:71.
8. Melville JL, Walker E., Katon W, et al. Prevalence of comorbid psychiatric illness and its impact on symptom perception, quality of life and functional status in women with urinary incontinence. *Am J Obstet Gynecol* 2002; 187:80.
9. Wagner TH, Hu TW. Economic costs of urinary incontinence in 1995. *Urology* 1998; 51:355.
10. Madersbacher S, Pycha A, Schatzl G, et al. The aging lower urinary tract: a comparative urodynamic study of men and women. *Urology* 1998; 51:201.
11. Baden WF, Walker T. Grading support loss: the halfway system: in Baden WF, Walker T (eds): *Surgical repair of vaginal defects*. Philadelphia, Lippincott 1992, pp 339-357.
12. Abrams P, Cardozo L, Fall M, et al. The standardisation of terminology of lower urinary tract function: report from the standardisation sub-committee of the international continence society. *Neurourol Urodyn* 2002; 1:167.
13. Stohrer M, Goepel M, Kondo A, et al. The standardization of terminology in neurogenic lower urinary tract dysfunction with suggestions for diagnostic procedures. *Neurourol Urodyn* 1999; 18:139.
14. Schafer W, Abrams P, Liao L et al. Good urodynamic practices: uroflowmetry, filling cystometry, and pressure-flow studies. *Neurourol Urodyn* 2002; 21:261.
15. Ho-Hsiung L, Pao-Ling T, Bor-Ching S, et al. Uroynamically age-specific prevalence of urinary incontinence in women with urinary symptoms. *Neurourol Urodyn* 2003; 22:29.
16. Miller KL, DuBeau CE, Bergmann M, et al. Quest for a detrusor overactivity index. *J Urol* 2002; 167:578.
17. Melville JL, Katon W, Delaney K, et al. Urinary incontinence in US women: a population-based study. *Arch Intern Med* 2005; 165:537-42.
18. Van Brummen HJ, Heintz APM, Van der Vaart CH. The association between overactive bladder symptoms and objective parameters from bladder diary and filling cystometry. *Neurourol Urodyn* 2004; 23:38.
19. Matharu G, Donaldson MM, McGrother CW, et al. Relationship between urinary symptoms reported in a postal questionnaire and urodynamic diagnosis. *Neurourol Urodyn* 2005; 24:100.
20. Collas DM, Malone-Lee JG. Age-associated changes in detrusor sensory function in women with lower urinary tract symptoms. *Int Urogynecol J Pelvic Floor Dysfunct* 1996; 7:24.
21. Pfisterer MHD, Griffiths DJ, Schaefer W, et al. The effect of age on lower urinary tract function: a study in women. *JAGS* 2006; 54:405.
22. Long-Yau L, Nan-Hung Y, Ching-Yi L, et al. Comparisons of urodynamic characteristics between female patients with overactive bladder and overactive bladder plus stress urinary incontinence. *Urology* 2004; 64:945.
23. Elbadawi A, Yalla SV, Resnick NM. Structural basis of geriatric voiding dysfunction. III: Detrusor overactivity. *J Urol* 1993; 150:1668.
24. Geirsson G, Fall M, Lindstrom S. Subtypes of overactive bladder in old age. *Age Ageing* 1993; 22:125.
25. Hampel C, Gillitzer R, Pahernik S, et al. Epidemiology and etiology of overactive bladder. *Urologe A* 2003; 42:776.
26. Rudt T. Urethral pressure profile in continent women from childhood to old age. *Acta Obstet Gynecol Scand* 1980; 59:331.
27. Brown KH, Hammond CB. Urogenital atrophy. *Obstet Gynecol Clin North Am* 1987; 14:13.
28. Jarmy-Di Bella ZI, Girao MJ, Di Bella V, et al. Hormonal influence on periurethral vessels in postmenopausal incontinent women using Doppler velocimetry analysis. *Maturitas* 2007; 56:297.
29. Goepel C, Thomssen C. Changes in the extracellular matrix in periurethral tissue of women with stress urinary incontinence. *Acta Histochem* 2006; 108:441.
30. Seidlova-Wuttke D, Schultens A, Jerry H, et al. Urodynamic effects of estradiol (E²) in ovariectomized (OVX) rats. *Endocrine* 2004; 23:25.
31. Parazzini F, Chiaffarino F, Lavezzari M, et al. Risk factors for stress, urge or mixed urinary incontinence in Italy. *BJOG* 2003; 110:927.
32. Melville JL, Katon W, Delaney K, et al. Urinary incontinence in US women: a population-based study. *Arch Intern Med* 2005; 145:537.
33. Elia G, Dye TD, Scariati PD. Body mass index and urinary symptoms in women. *Int Urogynecol J Pelvic Floor Dysfunct* 2001; 12:366.
34. Moller LM, Lose G, Jorgensen T. Risk factors of lower urinary tract symptoms in women aged 40-60 years. *Ugeskr Laeger* 2001; 163:6598.
35. Jelovsek JE, Barber MD, Paraiso MF, et al. Functional bowel and anorectal disorders in patients with pelvic organ prolapse and incontinence. *Am J Obstet Gynecol* 2005; 193:2105.
36. Jackson SL, Weber AM, Hull TL, et al. Fecal incontinence in women with urinary incontinence and pelvic organ prolapse. *Obstet Gynecol* 1997; 89:423.
37. Meschia M, Buonaguidi A, Pifarotti P, et al. Prevalence of anal incontinence in women with symptoms of urinary incontinence and genital prolapse. *Obstet Gynecol* 2002; 100:719.

Correspondence

Carlo Vecchioli-Scaladazza, MD
Corso Cavour, 66 - 62100 Macerata, Italy
cascave@alice.it

Carolina Morsetti, MD
Clinical Research, Jesi Hospital, Jesi, Italy

Risk of prostate cancer at first saturation re-biopsy in a patient with previous diagnosis of HGPIN.

Roberto Giulianelli¹, Stefano Brunori¹, Barbara Cristina Gentile¹,
Giorgio Vincenti¹, Stefano Nardoni², Teuta Shestani¹, Luca Mavilla¹,
Luca Albanesi¹, Francesco Attisani¹, Francesco Pisanti¹

¹ Division of Urology, Villa Tiberia Clinic, Rome, Italy;

² Histopathological Service, Villa Tiberia Clinic, Rome, Italy

Summary

Introduction: It is advisable to submit a patient with isolated HGPIN to re-biopsy every 3-6 months, performing an increasing number of samples in order to increase the detection rate. The aim of this study is to evaluate if the use of saturation needle biopsy technique may increase this rate.

Materials and methods: From January 2004 to June 2006, 780 patients with hypoecogenic nodule at TRUS and/or PSA values between 2.5 and 10 ng/ml, underwent TRUS 10-core prostate needle biopsy, performed by the same operator. Isolated HGPIN was detected in 26 cases (3.3%). Within a year all these patients underwent saturation needle re-biopsy. This procedure consisted of 24 samples obtained using a tru-cut needle 18 G under soft anesthesia by a major opiate. All the patients received a single dose of Levofloxacin per os before the biopsy and for the following 2 days.

Results: Prostate cancer was found in 8 (33.3%) of the 24 eligible patients: 40% showed a Gleason Score 6 and 60% > 7. Concerning PSA, we observed 35% of neoplasms for values between 2.5 and 3.9 ng/ml and the remaining 65.0% for values between 4.0 and 9.9 ng/ml.

Conclusions: The use of saturation needle biopsy allowed to detect 30.8% of prostatic cancer performing the first re-biopsy within a year. This result does not differ from others obtained with 8-10 cores techniques, therefore the indication of the 24-cores procedure should be limited to carefully selected patients with a high risk of developing cancer after that other techniques had not been successful.

KEY WORDS: Prostate cancer; Ultrasound guided transrectal core biopsy; Re-biopsy; Saturation biopsy; PCa detection rate; HGPIN.

Submitted 8 February 2010; Accepted 30 April 2010

INTRODUCTION

Since the advent of Prostatic Specific Antigen (PSA) screening there was a considerable prostate cancer migration versus the diagnosis of lower risk disease (1). The challenge now is to differentiate high risk patients avoiding clinically indolent disease overtreatment. The lack of consistently reliable radiological features in staging adenocarcinoma of the prostate resulted in the study of clinical variables such as PSA, Gleason Score, grade, clinical stage and, lately, biopsies (2). During the last decade a considerable number of modifications have been made to improve the technique of prostate cancer (PCa) biopsy. Studies showed that increasing the number of biopsy cores increased PCa detection rates (3). Total

prostate volume too is an important factor: higher PCa detection rate was reported in men with smaller prostates (4). Recent prospective (4) and retrospective (5) studies showed a PCa detection rate from 10% to 27% on repeated biopsies.

Several studies identified biopsy characteristics, including percent of positive biopsies and number of positive biopsies as strong independent risk category of pathological stage (6) and outcome after treatment such as radical prostatectomy or radiotherapy (7). Extended biopsy scheme and saturation biopsy strategy resulted in a greater than 30% PCa detection rate in men with previously negative sextant biopsies (8). Since the description

of High Grade Prostatic Intraepithelial Neoplasia (HGPIN) by McNeal and Bostwick in 1986, several studies reported about the positive predictive value of isolated HGPIN on repeated prostate needle biopsy, which ranged from 2.3% to 100% (6).

MATERIAL AND METHODS

In this study, 780 patients (age range 38-79 years) were enrolled from January 2004 to January 2006. Inclusion criteria were: PSA values > 2.5 ng/ml and < 10 ng/ml, a suspicious digital rectal examination (DRE) or TRUS ipoechogenic nodule. Exclusion criteria were: history of PCa, acute or chronic prostatitis, histological evidence of PIN (prostatic intraepithelial neoplasia), urinary retention, indwelling urinary catheter or confirmed urinary tract infection. All patients discontinued anti-coagulants 5 days before biopsy and received a single dose of fluoroquinolone (levofloxacin) before biopsy and the following two days after the procedure. Patients were fully informed and consented the procedure. TRUS guided biopsies were performed by the same surgeon (G.V.) using a tru cut 18 gauge needle in left lateral supine decubitus without local anesthesia. We performed 10-cores biopsies as described by Gore *et al.* (9) plus, if present, 2-cores biopsies on the ipoechogenic nodule. Of all these patients, 176 (22.6%) showed PCA and 540 patients (69.2%) were PCa free: 26 HGPIN (3.3%), 12 atypical small acinar proliferation (ASAP) (1.5%) and 502 (64.4%) benign prostatic hyperplasia. For a year all the 26 HGPIN patients were included in a follow-up protocol consisting in PSA determination every 3 months, DRE every 6 months and, in the case of a modification of one of these parameters, a repeated ultrasound guided transrectal core biopsy of the prostate with saturation biopsy technique.

Prior to saturation biopsy clinical evaluation excluded acute or chronic prostatitis, urinary tract infection or lower urinary tract endoscopic procedures.

Patients were fully informed and consented the procedure. All patients discontinued anti-coagulants 5 days before biopsy and received antibiotic prophylaxis with a single dose of Levofloxacin.

TRUS guided 24-cores biopsies performed by the same surgeon (G.V.) using a tru cut 18 gauge needle in left lateral supine in the operating room under intravenous anesthesia by Remifentanyl (Ultiva, GlaxoSmithKline). This anesthesia technique increased the procedure compliance and reduced patient's discomfort. Biopsy were obtained on each side: 1) lateral base with 2 cores, 2) lateral mild zone with 3 cores, 3) apex with 3 cores, 4) parasagittal middle zone with 2 cores and 5) parasagittal base with 2 cores. We take care to assure that the 3 apical biopsies adequately sampled the anterior horn of the peripheral zone tissue. An experienced pathologist evaluated all the slides.

For each patient we evaluated PCa detection rates according to the PSA ranges. We also evaluated clinical outcome and postoperative complication rate (total postoperative hospital stay, haemoglobin loss, catheter time, pain rate, QoL). Clinical characteristics of the patients with detected cancer were recorded: PSA levels at diagnosis, presence of palpable tumour, Gleason score of pro-

static biopsy, volume, localization, percentage of tumour and number of involved cores. The presence of clinically insignificant cancer (defined as tumour volume less than 0.5 cc and Gleason score < 7) was estimated following the model of Epstein *et al.* (10), based on clinical and biopsy criteria: non-palpable cancer, F/T ratio greater than 0.15, less than 3 biopsy cores involved with no more than 50% and Gleason score < 7.

RESULTS

Of 26 patients with isolated High Grade PIN (HGPIN) only 24 (92.3%) were eligible for this study. Of these, 16 (66.7%) were cancer free and 8 (33.3%) showed adenocarcinoma of the prostate: 5 (20.8%) had Gleason score 4 or 5, 3 (12.5%) 6 or 7 and none from 8 to 10. The mean prostate volume measured by TRUS was 46.7 ± 17.8 cc and 11 of 24 patients (45.8%) presented an ipoechogenic nodule in peripheral zone tissue. Suspicious digital rectal examination was present in 7 cases (29.1%).

Concerning to PSA value, we observed 6 (25%) PCa patients and 2 (0.8%) disease free in the PSA range 2.5-3.9 ng/ml while in the PSA range 4.0-9.9 ng/ml. we observed 10 (41.6%) PCa patients and 6 (25%) tumour free, respectively.

Sectors apical biopsies carried out in the anterior horn of the peripheral zone tissue showed over 29% (7 patients) of cancer detection rate, while cancer was detected in 8.3% (1 patients) in lateral base tissue, 4.5% (1 patients) in lateral mild zone and in no sample of the parasagittal zone. In all patients we evaluated tumour volume biopsy cores, percentage of biopsy cores involvement and number of biopsy cores involved. In 3 (12.5%) patients we observed a tumour volume < 0.5 cc, in other 3 (12.5%) volume tumour between 0.5 and 1 cc and in 2 (8.3%) volume tumour > 1 cc.

In 3 (12.5%) patients we evaluated a percentage of involvement of biopsy cores > 50%, in 5 (20.8%) < 50%. Only three (12.5%) patients presented more than 3 positive biopsies cores, and 5 (20.8%) < 3. We observed only 2 (8.3%) patients with tumour volume < 0.5 cc, < 5% of involvement and only one biopsy core involved; 2 (8.3%) patients with tumour volume < 0.5 cc, 25% of involvement and 2 biopsy cores involved; 1 (4.16%) with tumour volume > 0.5 cc, > 50% of involvement and more than 3 biopsy cores.

A total of 7 (29.1%) patients underwent radical retropubic prostatectomy and only one (4.16%) was treated by external beam radiation therapy (tumour volume < 0.5 cc, 25% of involvement and 2 biopsy cores involved). Final examination of the specimen showed that cancer was clinically significant in 4 patients (16.6%) and 3 of them presenting an organ confined tumour after radical surgery.

No residual cancer was identified on the final surgical specimen in one case (2%) who presented to saturation biopsy a tumour volume < 0.5 cc with 5% of involvement and one biopsy cores involved.

DISCUSSION

Many papers in Literature demonstrate that HGPIN is a precursor lesion of prostate cancer (11) and several stud-

ies reported about the positive cancer predictive value of isolated HGPIN on repeated prostate needle biopsy, with rates ranging from 2.3% to 100% (8, 11-12).

Recommendations about the follow-up in men with isolated HGPIN on initial biopsy vary widely from immediate re-biopsy to re-biopsy after 3 to 6 months, after 6 to 12 months, or after 3 years (13, 14). In most recent studies, PCa detection rates in HGPIN patients re-biopsies, after sextant sampling, range from 20% to 30% (8). In our saturation biopsy experience, after a first one 12-core sampling, we found a cancer detection rate of 33.3% within one year from the initial HGPIN diagnosis.

REFERENCES

1. Cooperberg MR, Lubeck DP, Carroll PR. Times trends in clinical risk stratification for prostate cancer implications for outcomes (data form Capsure). *J Urol* 2003; 170:821.
2. Graefen M, Otori M, Karakiewicz PI, et al. Assessment of the enhancement in predictive accuracy provided by systematic biopsy in predicting outcome for clinically localized prostate cancer. *J Urol*, 2004; 171:200.
3. Eskew IA, Bare RL, McCollough D, et al. Systematic 5 region prostate biopsy is superior to sextant method for diagnosing carcinoma of the prostate. *J Urol* 1997; 157:199.
4. Djavan B, Zlotta A, Remzi M, et al. Optimal predictors of prostate cancer on repeat prostate biopsy: a prospective study in 1051 men. *J Urol* 2000; 163:1144.
5. Borboroglu PG, Comer SW, Riffenburgh RH, et al. Extensive repeat transrectal ultrasound guided biopsy in patients with previous benign sextant biopsies. *J Urol* 2000; 163:152.
6. Grossfield GD, Chang JJ, Broering JM, et al. Under staging and under grading in a contemporary series of patients undergoing radical prostatectomy: results from the Cancer of the Prostate Urologic Research Endeavor database. *J Urol* 2001; 165:851.
7. D'Amico AV, Whittington R, Malkowicz SB, et al. Clinical utility of percent-positive prostate biopsies in predicting biochemical outcomes after radical prostatectomy or external-beam radiation therapy for patients with clinically localized prostate cancer. *Mol Urol*, 2000; 4:171.
8. Bishara T, Ramnani DM, Epstein JI. High-grade prostatic intraepithelial neoplasia on needle biopsy risk of cancer on repeat biopsy related to number of involved cores and morphologic pattern. *Am J Surg Pathol*, 2004; 28:629.
9. Gore JL, Shariat SF, Miles BJ, et al. Optimal combination of systematic sextant and laterally directed biopsies for the detection of prostate cancer. *J Urol* 2001; 165:1554.
10. Epstein JI, Chan DW, Sokoll LJ, et al. Nonpalpable stage T1c prostate cancer: prediction of insignificant disease using free/total prostate specific antigen levels and needle biopsy findings. *J Urol* 1998; 160(6 Pt 2):2407-11.
11. Bostwick D, Qian J. High-grade prostate intraepithelial neoplasia. *Mod Pathol* 2004; 17:360.
12. Sidhu GS, Torre P, Lepor H, et al. Is repeat prostate biopsy for high-grade prostatic intraepithelial neoplasia necessary after routine 12-core sampling? *Urology* 2001; 58:999.
13. Aboseif S, Shinohara K, Weidner N, et al. The significance of prostatic intra-epithelial neoplasia. *Br J Urol* 1995; 76:355.
14. Lefkowitz GK, Taneja SS, Brown J, et al. Follow-up interval prostate biopsy 3 years after diagnosis of high grade prostatic intraepithelial neoplasia in associated high likelihood of prostate cancer; independent of change in prostatic specific antigen levels. *J Urol* 2002; 168:1415.

Correspondence

Roberto Giulianelli, MD

Division of Urology - Villa Tiberia Clinic, Rome, Italy
roberto.giulianelli@virgilio.it

Stefano Brunori, MD

Division of Urology - Villa Tiberia Clinic, Rome, Italy

Barbara Cristina Gentile, MD

Division of Urology - Villa Tiberia Clinic, Rome, Italy

Giorgio Vincenti, MD

Division of Urology - Villa Tiberia Clinic, Rome, Italy

Stefano Nardoni, MD

Histopathological Service - Villa Tiberia Clinic, Rome, Italy

Teuta Shestani, MD

Division of Urology - Villa Tiberia Clinic, Rome, Italy

Luca Mavilla, MD

Division of Urology - Villa Tiberia Clinic, Rome, Italy

Luca Albanesi, MD

Division of Urology - Villa Tiberia Clinic, Rome, Italy
lucalbanesi@hotmail.com

Francesco Attisani, MD

Division of Urology - Villa Tiberia Clinic, Rome, Italy

Francesco Pisanti, MD

Division of Urology - Villa Tiberia Clinic, Rome, Italy
francesco.pisanti@fastwebnet.it

Laparoscopic heminephrectomy in horseshoe kidney: A case report.

Dario Del Biondo, Antonio Celia, Guglielmo Zeccolini, Guglielmo Breda

Department of Urology San Bassiano Hospital, Bassano del Grappa (VI), Italy

Summary

We present a case of laparoscopic transperitoneal heminephrectomy involving a large renal cell carcinoma of 7 cm centrally located on the left side of a horseshoe kidney in a 48 years old male patient detected by ultrasound scan and CT scan.

KEY WORDS: Laparoscopy; Horseshoe kidney; Eminephrectomy.

Submitted 16 November 2009; Accepted 15 March 2010

INTRODUCTION

Horseshoe kidney (HK) is one of the most common and best known congenital renal fusion anomalies. Its aberrant vasculature, abnormal kidney location and renal isthmus present technical challenges to the laparoscopic management of horseshoe kidneys. To date, there are only three reports of relatively small renal-cell carcinomas excised from horseshoe kidneys using the laparoscopic approach. We describe our experience of laparoscopic transperitoneal heminephrectomy involving a large renal cell carcinoma of 7 cm centrally located on the left side of a horseshoe kidney demonstrating that laparoscopic heminephrectomy is a safe and effective method for the surgical management of the horseshoe kidneys.

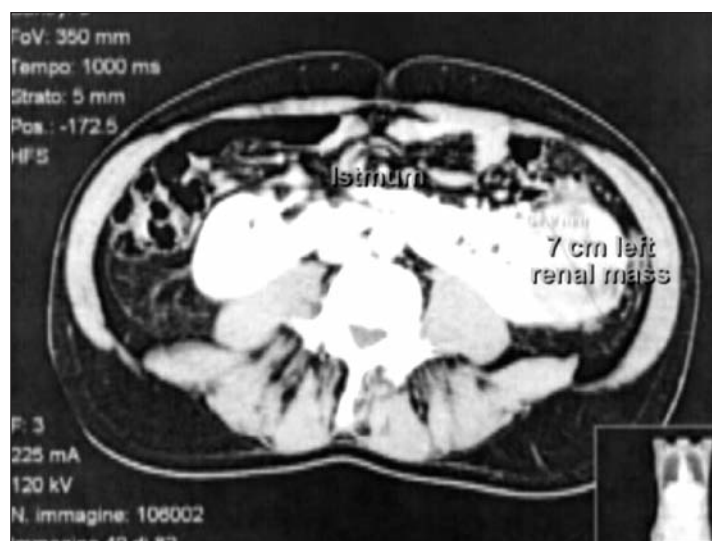
CASE REPORT

A 48 years old male patient with a horseshoe kidney was admitted to our Departement with left-sided lumbar pain. A renal mass of 7 cm centrally located on the left side of the horseshoe kidney was detected by Ultrasound scan and CT scan (Figure 1). The patient was elected to undergo a laparoscopic transperitoneal left heminephrectomy. Traditionally, the transperitoneal route affords an optimal working space and facilitates orientation by providing readily identifiable anatomic landmarks.

Under general anesthesia, after introduction of orogastric tube and Foley catheter, the patient was placed in lateral decubitus position on the right side. We got peritoneal space access and

carbon dioxide pneumoperitoneum (15 mm Hg CO²) according to Hasson technique. We chose for the transperitoneal laparoscopic approach a 4-ports L-shaped configuration with 4 trocars positioned as usual: 3 trocars were placed on the midclavicular line from up to down respectively at 16 cm, 8 cm and at the same level of the umbilicus and 8 cm lateral from this trocar we put

Figure 1.
TC: renal mass of 7 cm centrally located on the left side of the horseshoe kidney.



the fourth. The white line of Toldt was incised from the level of the iliac vessels to above the spleen including the lienocolic ligament. The operation started by medializing left colon. Medial traction on the colon revealed colorenal attachments that had to be divided to complete the colon dissection. Adequate mobilization of the colon revealed the psoas muscle followed by the detection of the gonadic vein and the left ureter. The ureter was elevated and followed proximally to the lower pole and hilum of the kidney. The pedicle vessels were identified, isolated, clipped and divided individually after a meticulous hilar dissection. During dissection behind isthmus, an additional artery, going to the inferior pole of both hemi-kidneys, was found. The branch irrigating the left hemi-kidney was ligated by clips and split. Once the hilar vessels were divided, the dissection continued posteriorly and superiorly to the upper pole and the adrenal gland was preserved. The whole kidney was isolated outside from the Gerota fascia. The isthmus, after being tied by 2 endoloops, was resected (Figure 2). Careful hemostasis was performed on the resected bed of the isthmus.

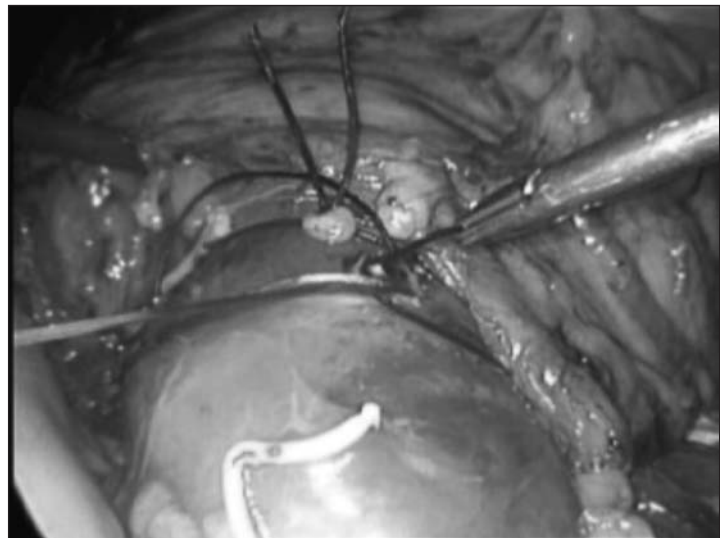
The result was a total hemostasis at the site of division, and no additional hemostatic measure was required. Resected kidney was removed by endobag. The operative time was 210 minutes, and the estimated blood loss was 100 cc. There were no immediate or delayed complications. Although renal cell carcinoma occurs infrequently in such kidneys, pathological examination of the specimen confirmed a 7 cm organ-confined clear cell carcinoma with sarcomatoids areas (pT2 Furhman2 NO Mx). After 12 months of follow-up, the patient was disease free.

DISCUSSION

Horseshoe kidney results from the fusion of the embryonic kidneys, most commonly at the inferior pole. The incidence is 1:400 to 1:1000 (1). The incidence in the urology patient population is 1/300. The condition is most common in males, and most cases are sporadic (no clear hereditary pattern). The age at presentation varies and depends on the underlying complication and the severity of the symptoms. Although most horseshoe kidneys are asymptomatic, they may present with a complication such as ureteropelvic junction obstruction, pyonephrosis, urolithiasis, or malignancy. When surgery is contemplated for renal-cell carcinoma in such kidneys (2-3), aberrant vasculature and isthmusectomy are the major issues to consider. In surgery on normal kidneys, the use of minimally invasive techniques has decreased morbidity and improved postoperative care. However, aberrant vasculature, abnormal kidney location, and the renal isthmus present technical challenges to the laparoscopic management of horseshoe kidneys (4). To date, there are only three reports of relatively small renal-cell carcinomas excised from horseshoe kidneys using the laparoscopic approach. Two were performed using a retroperitoneal approach, and one using

Figure 2.

Resection of the isthmus tied by 2 endoloops.



a transperitoneal approach (5-7). This choice depends on location of the tumor. We describe as laparoscopic approach by transperitoneal route for the treatment of a large renal mass (7 cm) in an horseshoe kidney performed in our clinic showed to be a feasible and effective surgical solution. The aim of this description is to highlight how during laparoscopic partial nephrectomy of a horseshoe kidney, precise identification of number, location, and extrarenal anatomy of the renal arteries and veins is necessary for achieving reliable vascular control (8-10).

CONCLUSION

Laparoscopy has greatly evolved over the years. Now laparoscopic approach can be used to treat large tumors in horseshoe kidneys too. The aberrant vessels, the renal isthmus, and the renal ectopia are unique features of this anomaly that make the laparoscopic approach a challenge. Good laparoscopic skills and patience are required to manage the multiple blood vessels and to control the isthmus. These techniques, if performed in experienced laparoscopic centers, have the benefit of the reduction in operative trauma and organ affliction, resulting in greater patient comfort, shorter postoperative course, and shorter convalescence in complicated urological pathologies.

REFERENCES

1. Dasgupta R, Shrotri N, Rane A. Hand-assisted laparoscopic heminephrectomy for horseshoe kidney. *J Endourol* 2005; 19:484-5.
2. Breda A, Stepanian SV, Liao J, et al. Positive margins in laparoscopic partial nephrectomy in 855 cases: a multi-institutional survey from the United States and Europe. *J Urol* 2007; 178:47-50.
3. Breda A, Finelli A, Janetschek G, et al. Complications of laparoscopic surgery for renal masses: prevention, management, and comparison with the open experience. *Eur Urol* 2009; 55:836-50.
4. Yohannes P, Dinlenc C, Liatsikos E, et al. Laparoscopic hem-

inephrectomy for benign disease of the horseshoe kidney. *JSL* 2002; 6:381-4.

5. Kitamura H, Tanaka T, Miyamoto D, et al. Retroperitoneoscopic nephrectomy of a horseshoe kidney with renal-cell carcinoma. *J Endourol* 2003; 17:907-8.

6. Molina WR, Gill IS. Laparoscopic partial nephrectomy in a horseshoe kidney. *J Endourol* 2003; 17:905-6.

7. Araki M, Link BA, Galati V, et al. Case report: hand-assisted laparoscopic radical heminephrectomy for renal-cell carcinoma in a horseshoe kidney. *J Endourol* 2007; 21:1485-7.

8. Tan YH, Young MD, Preminger GM, et al. Hand-assisted laparoscopic heminephrectomy in horseshoe kidney. *J Endourol* 2004; 18:562-4.

9. Breda A, Lam JS, Veale J, et al. Laparoscopic heminephrectomy for upper-pole moiety in children using a 3-mm laparoscope and instruments. *J Endourol* 2007; 21:883-5.

10. Patankar S, Dobhada S, Bhansali M. Case report: laparoscopic heminephrectomy in a horseshoe kidney using bipolar energy. *J Endourol* 2006; 20:639-41.



Correspondence

Dario Del Biondo, MD

Department of Urology, San Bassiano Hospital
Bassano del Grappa (VI), Italy

Antonio Celia, MD

Department of Urology, San Bassiano Hospital
Bassano del Grappa (VI), Italy
antoniocelia@virgilio.it

Guglielmo Zeccolini, MD

Department of Urology, San Bassiano Hospital
Bassano del Grappa (VI), Italy

Guglielmo Breda, MD

Department of Urology, San Bassiano Hospital
Bassano del Grappa (VI), Italy

Fibrous pseudotumor originating from tunica albuginea testis: A case report.

Yusuf Özlem İlbey¹, Emin Özbek¹, Emre Can Polat¹, Abdulmuttalip Şimşek¹, Adnan Somay²

Bezm-i Alem Valide Sultan Vakıf Gureba Research and Education Hospital, Department of Urology¹ and Pathology², Istanbul, Turkey

Summary

We report the case of 33 year-old man who presented a rare benign paratesticular mass identified as fibrous pseudotumor. Because of its rarity, the clinical, diagnostic and therapeutic aspects as well as the possibilities of organ-sparing surgery are discussed.

KEY WORDS: Paratesticular tumors; Pseudotumors; Testis; Tunica albuginea.

Submitted 8 July 2009; Accepted 30 September 2009

INTRODUCTION

Paratesticular tumors originate in structures that contain connective tissue around the testis, epididymis or spermatic cord. Fibrous pseudotumors are among the rarest in this group, comprising approximately 6% (1). Most reported cases involved the tunica vaginalis; rarely it is associated with tunica albuginea, epididymis or spermatic cord (1-3). We report a rare case in that lesions were emanating directly from the tunica albuginea testis, which is exceedingly rare (4).

CASE REPORT

A 33-year-old man presented to the urology service with a 6-months history of enlarging palpable mass in the left hemiscrotum without associated pain. He denied any history of scrotal trauma, infection or surgery. His physical examination was unremarkable, except for a 4 cm nontender intratesticular mass at the lower pole. Scrotal ultrasonography showed a 35 x 42 mm hypoechoic non-vascular mass attached to the lower pole of the left testis. Serum tumor markers including alpha-fetoprotein, beta-human chorionic gonadotrophin, and lactate dehydrogenase, were all within normal limits.

The patient subsequently underwent left testicular exploration. The mass emanated directly from the tunica albuginea, and there was no involvement of epididymis or tunica vaginalis. Intraoperative frozen section analysis of the mass showed no evidence of malignancy but revealed benign fibrosis.

Microscopic examination revealed that nodular fibrous

tumor separated from testicular tissue with fibrous regular capsula (Figure 1), and irregular cells in colloginezed basement (Figures 2, 3). There mitosis, cellular atypia or malign characteristics were identified. On immunohistochemical analysis, spindle cells showed intense positivity for alpha-smooth muscle actin (SMA) (Figure 4). No reactivity in these cells was detected for desmin, and no staining was observed for S-100 and CD34 proteins. These findings were consistent with fibrous pseudo

Figure 1.

Nodular fibrous tumor separated from testicular tissue with fibrous regular capsula (H-E X 40).


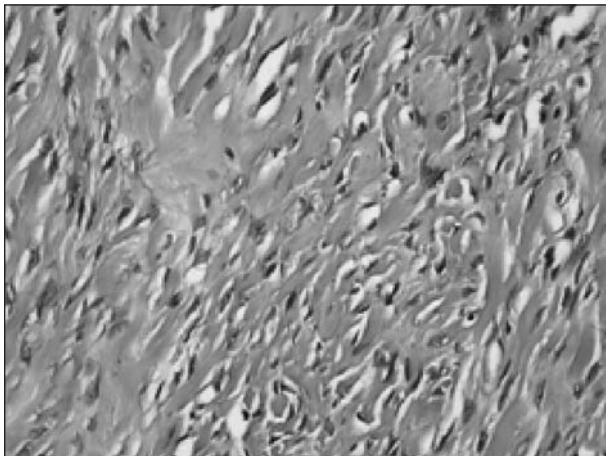


Figure 2.

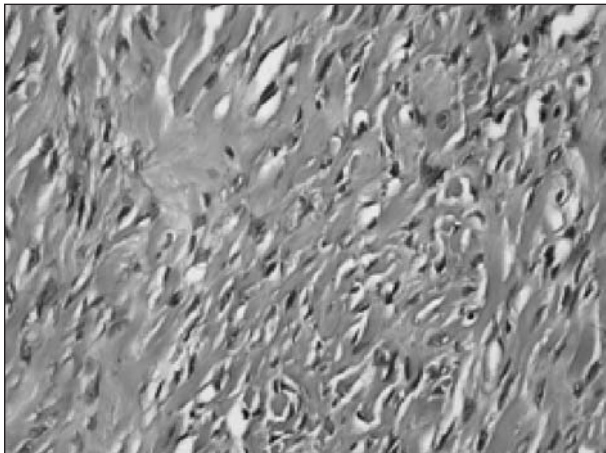
Irregular spindle cells in collagenized basement (H-E X 100).

**Figure 3.**

In collagenized basement extended, oval nucleated, undistinguished cytoplasmic bordered spindle cells (H-E X 400).

**Figure 4.**

The majority of spindle cells are SMA positive (Immunohistochemical staining X 200).



tumor of the tunica albuginea testis. At 12 months of follow-up, the patient was asymptomatic without any evidence of recurrence.

CONCLUSION

We report this case because of the exceedingly rarity of pseudotumors of testis and the importance of organ-sparing surgery by intraoperative frozen section analysis of the specimen. Most solid intratesticular masses are malignant. Hence, a testicular mass, especially if solid in ultrasonography, must be considered to be possibly malignant. Paratesticular tumors, although uncommon, comprise a heterogeneous group of benign and malignant lesions. In adult population, they constitute about 15% of intrascrotal lesions (5), and 20% about these tumors are malignant (6). Paratesticular tumors can be difficult to distinguish from intratesticular lesions on physical examination alone or even with ultrasonography.

Although fibrous pseudotumors are rare, they are the second most common mass involving paratesticular tissue behind adenomatoid tumors (2, 3). These tumors have a peak incidence in the third decade of life but can occur at any age (4). They usually present as a painless mass, as seen here (4). Ultrasound may demonstrate hypoechoic or hyperechoic lesions, depending on the degree of collagen or fibroblasts (2).

Macroscopically, the lesions are nodular, well delimited, ovoid, mobile structures. They may be single or multiple and occasionally will involve diffuse band-like fibrosis of the testicular tunics with encasement of testicle (2, 3). Under microscopic examination, fibrous tissue, spindle cells, plasma cells, and lymphocytes are commonly present, sparse in number, and engulfed within a keloid-like collagen (7). Histologic staining will identify multiple fibroblasts, intermixed with a few inflammatory cells in dense fibrous tissue, an apparent product of myofibroblastic proliferation. The primary purpose of the immunohistochemical studies was to analyze the phenotypic nature of the spindle cells that provide the largest portion of the lesion. These spindle cells are highly positive for vimentin and SMA, (2, 4, 8), and negative for S-100, keratin and desmin (8), as seen here.

Treatment includes the excision of the mass with a portion of the testis. As with this case, by considering rare benign intratesticular tumors in the differential diagnosis of the testicular masses, normal levels of preoperative serum tumor markers combined with intraoperative frozen section can organ-sparing surgery to be safely performed on these benign lesions.

REFERENCES

1. Tobias-machado M, Corrêa Lopes Neto A, Heloisa Simardi L, et al. Fibrous pseudotumor of tunica vaginalis and epididymis. *Urology* 2000; 56:670-2.
2. Seethala RR, Tirkes AT, Weinstein S, et al. Diffuse fibrous pseudotumor of the testicular tunics associated with an inflamed hydrocele. *Arch Pathol Lab Med* 2003; 127:742-4.
3. Rubenstein RA, Dogra VS, Seftel AD, et al. Benign intrascrotal lesions. *J Urol* 2004; 171:1765-72.

4. Polsky MS, Ball TP Jr, Smith RB, et al. Benign fibrous paratesticular tumors. *Urology* 1976; 8:174-6.
5. McClellan DS, Roscher A. Intrascrotal tumors in the older male. *Int Surg* 1986; 71:51-2.
6. Lioe TF, Biggart JD. Tumours of the spermatic cord and paratesticular tissue. A clinicopathological study. *Br J Urol* 1993; 71:600-6.
7. Orosz Z, Besznyák II. Diffuse Inflammatory Pseudotumor of the Testis, the Epididymis and the Spermatic Cord. *Pathol Oncol Res* 1995; 1:75-9.
8. Jones MA, Young RH, Scully RE. Benign fibromatous tumors of the testis and paratesticular region: a report of 9 cases with a proposed classification of fibromatous tumors and tumor-like lesions. *Am J Surg Pathol* 1997; 21:296-305.



Correspondence

Yusuf Özlem İlbey, MD
Department of Urology
Vakıf Gureba Research & Education Hospital
Fatih-Istanbul, Turkey
ozlemyusufilbey@hotmail.com

Emin Özbek, MD
Department of Urology
Vakıf Gureba Research & Education Hospital
Fatih-Istanbul, Turkey
ozbekemin@hotmail.com

Emre Can Polat, MD
Department of Urology
Vakıf Gureba Research & Education Hospital
Fatih-Istanbul, Turkey
dremrecan@hotmail.com

Abdullah Şimşek, MD
Department of Urology
Vakıf Gureba Research & Education Hospital
Fatih-Istanbul, Turkey
simsek76@yahoo.com

Adnan Somay, MD
Department of Pathology
Vakıf Gureba Research and Training Hospital,
Vatan Caddesi, 34095 - Aksaray, Istanbul, Turkey
adnansomay@yahoo.com

Management of large prostatic abscess associated with urethral stenosis and penile cancer recurrence

Andrea Benedetto Galosi, Gianni Parri, Vito Lacetera, Giovanni Muzzonigro

Institute of Urology, School of Medicine, Polytechnic University of Marche Region, Azienda Ospedaliero-Universitaria Ospedali Riuniti, Ancona, Italy

Summary

Introduction: The purpose of this report was to analyze the management of a large prostatic abscess in a patient with urethral stenosis and recurrence of penile cancer, who had presented with acute urinary retention.

Methods: The clinical diagnosis was based on the end-fire transrectal ultrasound (TRUS) findings and later confirmed by CT. The patient had several surgical scars and radiation-induced effects in the lower abdomen, therefore the placement of a percutaneous sovrapubic catheter was considered hazardous. The placement of a transurethral catheter was impossible because of firm meatal stenosis due to previous penile partial amputation and growing tissue that suggested local recurrence of penile cancer.

Results: Transurethral placement of a 8 Fr catheter was possible under radiologic/ultrasound control using a hydrophilic guidewire. The definitive treatment also included percutaneous transperineal drainage and placement of a 8 Fr pig-tail drain under TRUS. Subsequent surgical treatment of the penis showed low grade superficial squamous cell carcinoma. Management and follow-up of prostatic abscess is based on TRUS imaging. After 4 years of follow-up, abscess recurrence was observed and treated with a urethral catheter and antibiotics.

Conclusion: Urethral stenosis due to penile cancer is a predisposing factor in the development of prostatic abscesses. Placement of a bladder catheter and percutaneous drainage of the abscess are the mainstays of treatment. In malignant urethral stenosis, the conservative management of a prostatic abscess is safe and efficacious in a long term follow-up. Transrectal US is a key instrument to guide intervention and to check results.

KEY WORDS: Interventional ultrasound; Prostate; Abscess; Penile neoplasms; Urethral stricture.

Submitted 30 April 2009; Accepted 30 June 2009

CASE REPORT

A 62-year-old man came to the emergency department complaining of lower abdominal pain and acute urinary retention. His medical history included penile cancer treated 8 years before with partial amputation, inguinal lymphadenectomy followed by external beam radiotherapy, hypertension, Type II diabetes mellitus, coronary artery disease, and appendectomy by midline laparotomy. Several days before presentation, he had started a course of ciprofloxacin for a presumed urinary tract infection. A very short penile shaft (4 cm in length) due to partial amputation and a midline abdominal surgical scar were observed. The prostate gland was very tender at the digital rectal examination.

Abdominal US revealed a distended bladder and a very

large collection of fluid causing the posterior bladder to bulge. It was not possible to insert a urethral catheter due to the firm meatal stenosis. The urethral meatus was narrow and covered by white fibrous tissue, which suggested penile cancer recurrence. The definitive diagnosis of a giant prostatic abscess was made using TRUS equipped with an end-fire probe (Figures 1B, 2C) and differential diagnosis with bladder diverticula was ruled out later by abdominal CT (Figures 2 A-B) and retrograde cystography.

The insertion of a sovrapubic catheter was not possible due to the high risk of sepsis and the risk of damage to the posterior bladder wall, which had been lifted by the fluid collection. Therefore an urethrogram was performed. A 4 cm

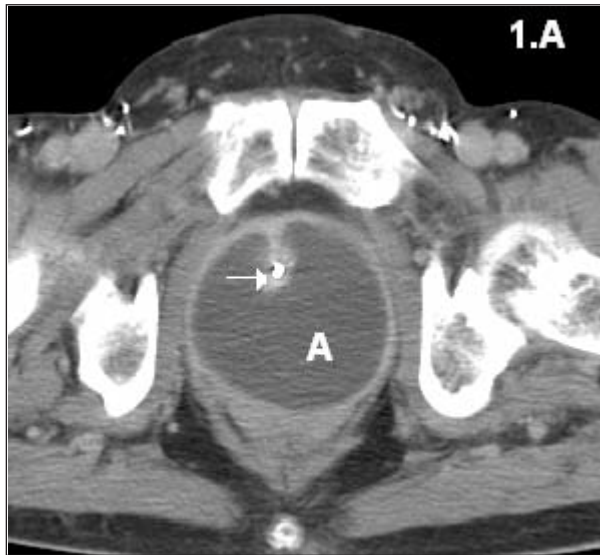

Figure 1A.

The contrast CT scan of the pelvis (axial view) shows abnormal enlargement of the prostate gland with large areas of relative low density. The urethra is indicated by white arrow.

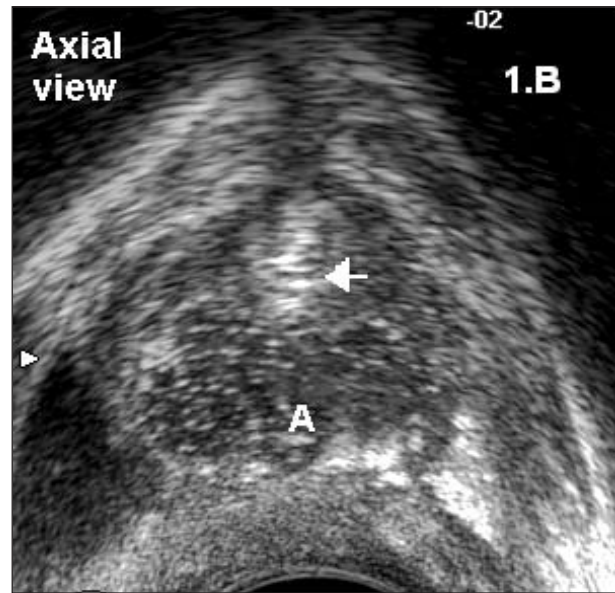


Figure 1B.

Axial view of prostatic abscess (A) using TRUS with end-fire probe. The urethra is indicated by white arrows.

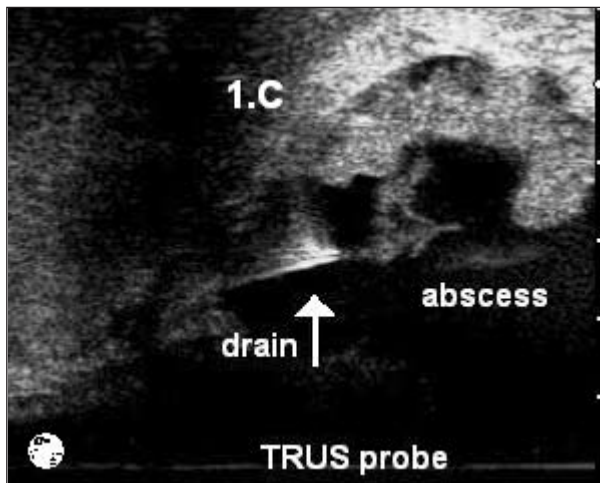


Figure 1C.

Transperineal placement of drain (white arrow) using TRUS equipped with linear probe, longitudinal view (perineal side is shown by white point).

long stenosis of the anterior urethra was detected (from the neo-meatus up to the bulbar urethra). Under radiologic control, an hydrophilic guidewire was passed through the stenosis and subsequently a 8Fr catheter was inserted to drain the bladder. Wide spectrum antibiotic therapy was started. Urine cultures would later grow *E. Coli*. Soon after the resolution of acute urinary retention, a contrast computed tomography (CT) scan was performed (Figures 1A, 2A-B). The contrast CT scan of the abdomen and pelvis showed abnormal enlargement of the prostate gland to approximately 8.3 x 5.1 cm, with large areas of rel-

ative low density. Additionally, there was an abnormal soft-tissue density extending posteriorly toward the rectum, with diffuse inflammatory stranding surrounding the area. Abundant fluid was identified inside the prostate but there was no gas.

Under local anaesthesia, transperineal drainage was performed with a 8 Fr pig-tail tube by TRUS control (biplane transrectal probe) (Figure 1C). Immediately 400cc of purulent fluid was drained. The drain output reduced progressively in the following 15 days. The drain was also used for irrigation with saline and antiseptic solution. The use of end-fire TRUS was helpful in monitoring the results of therapy (Figure 3). The transperineal drain was removed after 17 days.

The patient underwent surgery for resection of the recurrent penile cancer. The histopathology report described a penile well differentiated squamous cell carcinoma (pT1) with free surgical margins. Progressive urethral calibration was performed reaching a maximum of 16 Fr.

After 4 years of follow-up, the patient had a recurrence of prostatic abscess due to fibrous urethral stenosis, and this was treated successfully with urethral dilatation. After 5 years the patient was free of tumor recurrence and free of urinary tract infection.

DISCUSSION

Prostatic Abscesses (PA) are rare in the modern antibiotic era. PA are a very uncommon cause of acute urinary retention. The reported mortality rate varies between 1 and 16% (1-3).

Urethral stenosis due to penile cancer is a predisposing factor in the development of prostatic abscesses, along with other well-known factors: indwelling catheter, instrumentation of lower urinary tract, bladder outlet obstruc-

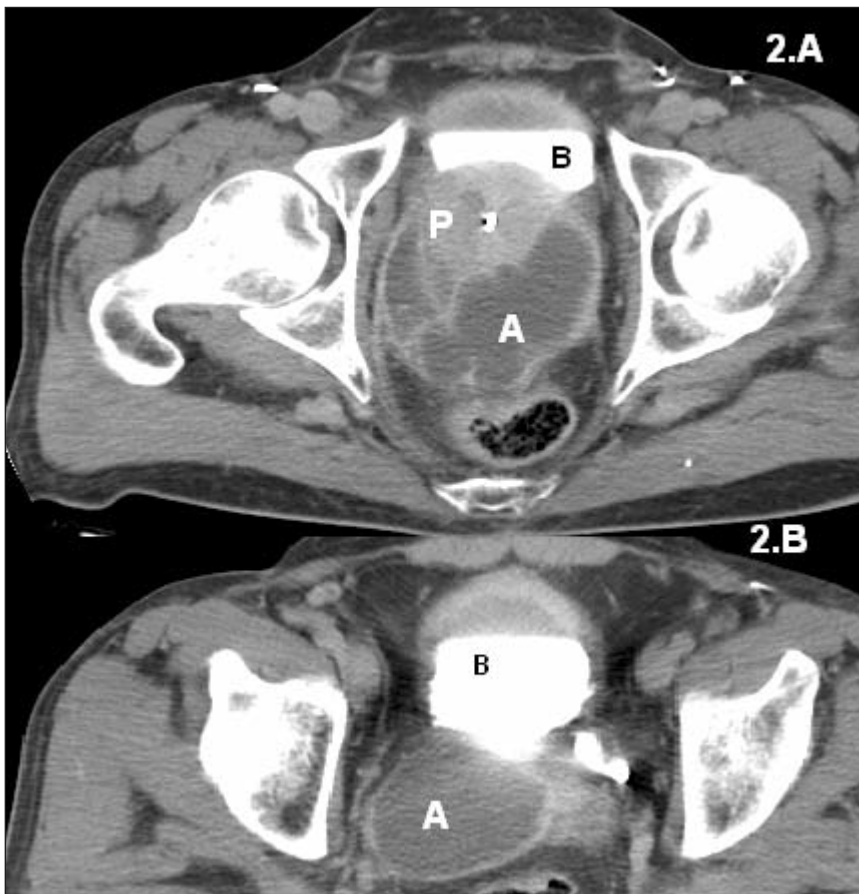
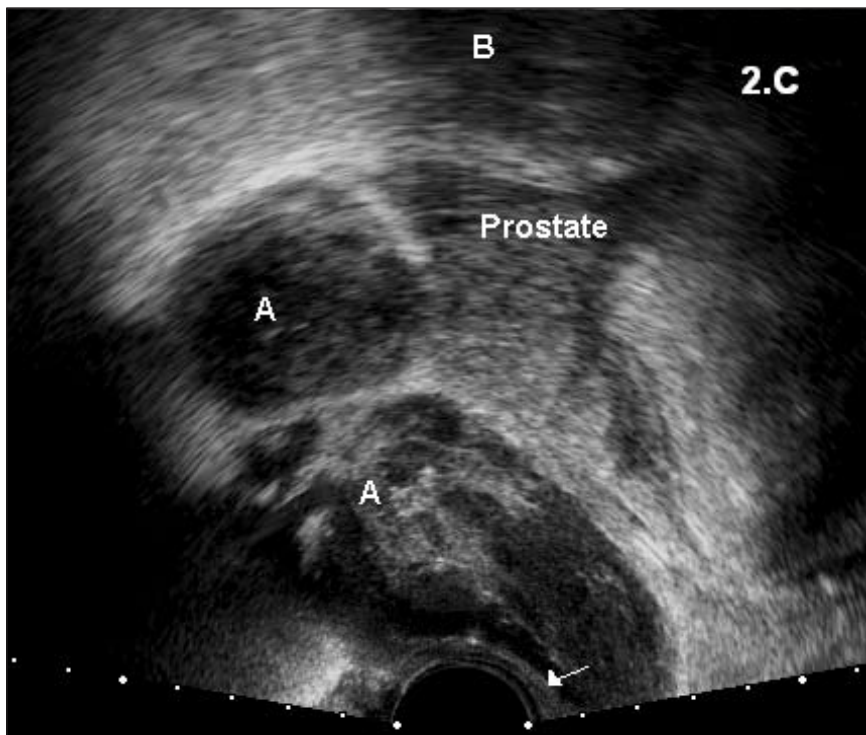


Figure 2A-B.

The contrast CT scan of the pelvis (axial view) show extensive fluid (A) in the prostate (P) and surrounding extraprostatic tissues. Bladder diverticula is ruled out as a result of differential diagnosis (lower image). B = bladder.



tion, bacterial prostatitis, chronic renal failure, hemodialysis, diabetes mellitus, cirrhosis and HIV infection (4).

Blind insertion of a transurethral Foley catheter seems to be a dangerous procedure because the catheter could damage the urethra which is thin and surrounded by fluid (Figure 1A), and the catheter could be inserted in the abscess cavity instead of the bladder. A misdiagnosis or wrong catheter placement could have serious effects including urethrorectal fistula formation from rupture of surrounding structures, sepsis, and, eventually, patient death (4-6).

In this case, the transurethral guidewire insertion under radiologic and ultrasound control was the safest procedure to allow the correct insertion of a thin urethral catheter. It had not been possible to use the standard treatment, i.e. suprapubic catheter and unroofing of the abscess with transurethral resection. The risk to damage the abscess with the insertion of the suprapubic catheter was high, because the abscess lifted the posterior bladder. Furthermore he received radiation therapy and midline laparotomy that made the suprapubic abdominal wall too stiff for the insertion of a suprapubic catheter. Moreover it was not possible to insert a 24Fr sheath in the urethra for transurethral resection.

Traditional radiologic studies in the clinical workup of a prostate abscess have included a CT scan or TRUS (6-8). A CT scan or MRI have significant risk factors or specific contraindications (contrast-induced nephropathy, costs, occasional unavailability in urology emergency rooms). Abdominal US

Figure 2C.

Longitudinal view of prostatic abscess (A) using TRUS with end-fire probe (white arrow = rectal wall).

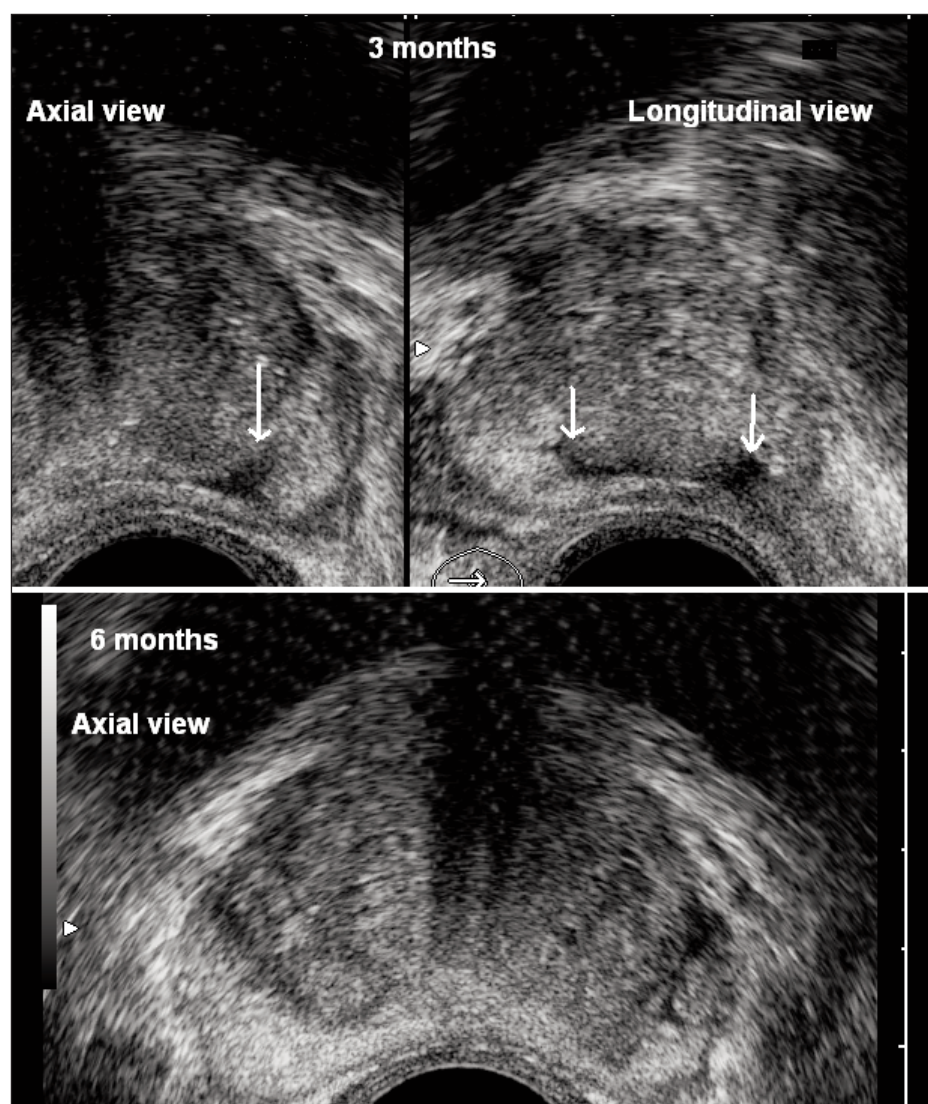


Figure 3.

Follow-up after 3 months (upper images): small anechoic area in the postero-lateral side of the left lobe using end-fire ultrasound probe (white arrows). After 6 months (lower image) the fluid has disappeared.

combined with TRUS has several advantages for these patients.

Transrectal ultrasound was considered potentially dangerous in this case because too much pressure on the rectal wall could have lead to septic shock. The insertion of the US probe in the rectum varies depending on whether an end-fire or linear (biplane) probe is used: the biplane probe is inserted blindly, while the end-fire probe can be inserted under ultrasound control monitoring the surrounding structures (rectal walls) that slip away. Usually, the pressure on the end-fire TRUS is similar to that of the finger during the rectal examination and can be considered a safe manoeuvre. End fire TRUS is for diagnostic propouse and useful for differential diagnosis with

emphysematous PA, which are characterized by gas formation (9).

Biplane TRUS is useful to guide the prostatic drain through the perineum.

A clear delineation of the extent of the disease and the involved structures is provided by a contrast-enhanced study by CT or MRI. In our opinion the end-fire TRUS is the best method for following up patients after treatment (Figure 3).

TRUS has advantages: low cost, good quality of imaging, without risk of radiation, easy available. Limits are poor detection of the abscess extension in the pelvis and other organs.

CONCLUSION

Urethral stenosis due to penile cancer is a predisposing factor in the development of prostatic abscesses, along with other well-known factors. Placement of a bladder catheter and percutaneous drainage of the abscess are the mainstays of treatment. In malignant urethral stenosis, the conservative management of a prostatic abscess is safe and efficacious in a long term follow-up. Transrectal US is a key instrument to guide intervention and to check results.

REFERENCES

1. Weinberger M, Cytron S, Servadio C, Block C, Rosenfeld JB, Pitlik SD: Prostatic abscess in the antibiotic era. *Rev Infect Dis* 1988; 10:239-49.
2. Barozzi L, Pavlica P, Menchi I, De Matteis M, Canepari M. Prostatic abscess: diagnosis and treatment. *AJR Am J Roentgenol* 1998; 170:753-7.
3. Granados EA, Riley G, Salvador J, Vincente J. Prostatic abscess: diagnosis and treatment. *J Urol* 1992; 148:80-2.
4. Jacobsen JD, Kvist E. Prostatic abscess: a review of literature and a presentation of 5 cases. *Scand J Urol Nephrol* 1993; 27:281-284.
5. Ludwig M, Schroeder-Printzen I, Schiefer HG, Weidner W: Diagnosis and therapeutic management of 18 patients with prostatic abscess. *Urology* 1999; 53:340-345.

6. Thornhill BA, Morehouse HT, Coleman P, Hoffman-Tretin JC. Prostatic abscess: CT and sonographic findings. *Am J Roentgenol* 1987; 148:899-900.
7. Cytron S, Weinberger M, Pitlik SD, Servadio C. Value of transrectal ultrasonography for diagnosis and treatment of prostatic abscess. *Urology* 1988; 32:454-8.
8. Bae GB, Kim SW, Shin BC, et al. Emphysematous prostatic abscess due to *Klebsiella pneumoniae*: report of a case and review of the literature. *J Korean Med Sci* 2003; 18:758-60.
9. Bhagat SK, Kekre NS, Gopalakrishnam G, Balaji V, Mathews MS. Changing profile of prostatic abscess. *Int Braz J Urol* 2008; 34:164-170.



Correspondence

Andrea B. Galosi, MD, PhD
Institute of Urology, AOU Ospedali Riuniti,
Via Conca 71 - I-60020 Torrette, Ancona, Italy
galosiab@yahoo.it

Gianni Parri, MD
Institute of Urology, AOU Ospedali Riuniti,
Via Conca 71 - I-60020 Torrette, Ancona, Italy
supergianetto@libero.it

Lacetera Vito, MD
Institute of Urology, AOU Ospedali Riuniti,
Via Conca 71 - I-60020 Torrette, Ancona, Italy
vitol78@libero.it

Giovanni Muzzonigro
Professor of Urology and Chief Institute of Urology
Institute of Urology, AOU Ospedali Riuniti,
Via Conca 71 - I-60020 Torrette, Ancona, Italy
g.muzzonigro@univpm.it

Chylous ascites following laparoscopic adrenalectomy: Case report and literature review.

Galanakis Joanny, Antonio Celia, Guglielmo Zeccolini, Dario Del Biondo, Guglielmo Breda

Department of Urology, San Bassiano Hospital, Bassano del Grappa (VI), Italy

Summary

We report a case of chylous ascites developing the first post-operative day after laparoscopic adrenalectomy. The early initiation of treatment with total parenteral nutrition and somatostatin analog led to rapid resolution of the ascites. To the best of our knowledge, this is the first case of chylous ascites after laparoscopic adrenalectomy and we report it to stress the need for greater awareness and attention (meticulous dissection, permanent use of hemoclips and/or suture ligatures instead of electrocautery) even for simpler laparoscopic urologic procedures.

KEY WORDS: Chylous ascites; Adrenalectomy; Laparoscopy.

Submitted 3 February 2010; Accepted 30 March 2010

INTRODUCTION

Post-operative chylous ascites is rarely encountered in urologic surgery. It is caused by an inadvertent trauma to the lymphatic system (chisterna chyli or other major retroperitoneal lymphatic channels) during complex surgical procedures. However, it may occur after less surgically demanding operations, such as adrenalectomy.

We present the first case, to our knowledge, of chylous ascites following laparoscopic adrenalectomy which was rapidly resolved with early administration of total parenteral nutrition and somatostatin analog. A brief review of the literature on the management of post-operative chylous ascites is also presented.

CLINICAL CASE

A 62-year-old patient was referred to our department with a diagnosed pheochromocytoma (5,5 cm in diameter) of the left adrenal and underwent laparoscopic left adrenalectomy. Surgical procedure was uneventful but on the first postoperative day, one liter of milky fluid was measured on the drainage sac.

The analysis of the ascitic fluid was consistent with chyle: pH 7,58, specific gravity 1.024, a total protein content of 3,8 g/dl, a triglyceride level of 1850 mg/dl, cholesterol at 58 mg/dl, leukocyte count 9500/mm³ with 84% lymphocytes, negative microbiologic cultures. Microscopic examination, after Sudan III staining,

revealed the presence of numerous lipid globules and leucocytes, predominantly lymphocytes. The treatment had already started consisting of total parenteral nutrition and octreotide 0,1mg x 3 s.c. The reduction of fluid amount was rapid and so was the change of its colour. On the fourth postoperative day the yellowish fluid from the drainage sac (200 ml) was examined again and the results showed no chyle.

We stopped total parenteral nutrition and placed the patient on a high protein, low fat, medium chain triglyceride diet which was continued along with the octreotide until he was discharged, fully recovered, 18 days post-operatively.

Two months after surgery, the patient is free of disease, showing no signs of chylous ascites.

DISCUSSION

Chylous ascites is defined as the accumulation of chyle in the peritoneal cavity. It is a rather rare condition accounting for between 1/20000 and 1/100000 of all hospital admissions (1).

The etiological factors can be broadly classified as congenital, neoplastic, infective, traumatic or post surgical. The most common cause of post-operative chylous ascites is surgery of the abdominal aorta (2). Regarding the urologic procedures, chylous ascites may present

after lymphadenectomy performed for testis cancer, radical nephrectomy or kidney donor nephrectomy because of inadvertent trauma to the cisterna chyli (the dilated part of the thoracic duct in the retrocrural space, at L1-L2 level) or its major tributaries (1-4).

Presentation of post-operative chylous ascites does not differ from ascites due to other causes, including progressive abdominal distention and weight gain, prolonged ileus, an abdominal fluid wave, a pleural effusion, or chylous leakage from the incision.

A clinical suspicion of chylous ascites can be confirmed by CT or MRI. However, the density of chyle is identical to water and as a consequence CT findings cannot differentiate between chylous ascites and ascites of other origin. The only pathognomonic sign in CT is the "fat fluid level", which may be demonstrated when the patient remains in dorsal decubitus for a prolonged period of time (5, 6).

Analysis of the ascitic fluid, obtained through paracentesis (or drainage), is the only way to confirm the diagnosis. It is typically milky, sterile, alkaline with a great triglyceride content (2-8 fold that of plasma) and a protein content greater than 3 g/dl. Microscopic examination after Sudan III staining reveals the presence of lipid globules and leucocytes, predominantly lymphocytes (2, 5).

The classical diagnostic modality for revealing lymphatic leakage has been the bipedal lymphography which uses ethiodized oil injected into lymphatic vessels on the dorsum of the foot (7).

It should be administered early in the course of evaluation, only when the diagnosis is in doubt. However, it is an invasive technique which gathers several disadvantages, resulting in the emergence of novel methods, such as lymphoscintigraphy (8). Lymphoscintigraphy is also used in follow-up, to document the reduction of chyle leakage postoperatively.

The management of chylous ascites remains controversial, primarily due to its rarity, and a variety of successful strategies has been reported.

However, in the opinion of most authors, the initial management of chylous ascites should be conservative aiming at reducing the lymphatic flow in the mesenteric lymphatic glands that join together in the disrupted major retroperitoneal and thoracic ducts-thereby limiting the leakage of lymph into the peritoneum.

Additional objectives of treatment are mechanical symptoms relief and the replacement of nutritional losses (2). Conservative measures include the use of repeated therapeutic paracentesis, dietary modification, diuretics, total parenteral nutrition and the use of somatostatin or its analogs.

Repeated paracentesis is not successful as a solitary measure.

Although its effect is impressive, it is transitory and has to be combined with other conservative measures in order to achieve resolution of chylous ascites. Nevertheless, in the review of Aalami, 7% of patients treated only with paracentesis achieved complete resolution (9).

Dietary intervention is the mainstay of conservative treatment. It consists of a high protein, low fat, medium chain

triglyceride diet which manages to decrease lymph flow in the major lymphatic tracts (10).

Total parenteral nutrition is another important conservative measure which is recommended by many authors as the initial treatment of choice (2, 11).

The early administration of somatostatin (or its analogues octreotide and lanreotide) results in a drastic reduction in the lymphatic fistula output within 24 to 72 hours of therapy (2).

The value and effectiveness of each separate conservative measure is difficult to quantify but when all or some of these measures are combined the success rate reaches the 67-90% of all cases, within a period of a few days to one year (1, 2, 9, 10, 12, 13).

When conservative treatment fails (deterioration of patient's condition or no fistula closure after several weeks), surgical intervention, either by inserting a peritoneovenous shunt or by direct suture ligation of the disrupted lymphatic channels, becomes rather mandatory (14).

CONCLUSION

Chylous ascites may develop even after not so complex urologic procedures, such as laparoscopic adrenalectomy, emphasizing the need for meticulous dissection and permanent use of hemoclips and/or suture ligatures instead of electrocautery, irrespectively of operation.

The early identification and initiation of proper conservative treatment for this complication may lead to rapid resolution.

Total parenteral nutrition (followed by a high protein, low fat, medium chain triglyceride diet) along with somatostatin analogs appears to be the most efficacious treatment.

REFERENCES

1. Evans JG, Spiess PE, Kamat AM, et al. Chylous ascites after post-chemotherapy retroperitoneal lymph node dissection: review of the M. D. Anderson experience. *J Urol* 2006; 176(4 Pt 1):1463-1467.
2. Leibovitch I, Mor Y, Golomb J, et al. The diagnosis and management of postoperative chylous ascites. *J Urol* 2002; 167(2 Pt 1):449-57.
3. Negoro H, Oka H, Kawakita M. Two cases of chyloretroperitoneum following retroperitoneoscopic nephroureterectomy. *Int J Urol* 2006; 13:487-9.
4. Wadström J. Hand-assisted retroperitoneoscopic live donor nephrectomy: experience from the first 75 consecutive cases. *Transplantation* 2005; 80:1060-6.
5. Ablan CJ, Littooy FN, Freeark RJ. Postoperative chylous ascites: diagnosis and treatment. A series report and literature review. *Arch Surg* 1990; 125:270-3.
6. Knight CG, Omert L. Chylous ascites after nephrectomy for trauma. *Am Surg* 2004; 70:1083-4.
7. Sachs PB, Zelch MG, Rice TW, et al. Diagnosis and localization of laceration of the thoracic duct: usefulness of lymphangiography and CT. *AJR Am J Roentgenol* 1991; 157:703-5.
8. Pui MH, Yueh TC. Lymphoscintigraphy in chyluria, chyloperitoneum and chylothorax: *J Nucl Med* 1998; 39:1292-6.

9. Aalami OO, Allen DB, Organ CH Jr. Chylous ascites: a collective review: *Surgery* 2000; 128:761-78.
10. Weiser AC, Lindgren BW, Ritchey ML, et al. Chylous ascites following surgical treatment for Wilms tumor. *J Urol* 2003; 170(4 Pt 2):1667-9.
11. Pabst TS 3rd, McIntyre KE Jr, Schilling JD, et al. Management of chyloperitoneum after abdominal aortic surgery. *Am J Surg* 1993; 166:194-8.
12. Baniel J, Foster RS, Rowland RG, et al. Complications of post-chemotherapy retroperitoneal lymph node dissection. *J Urol* 1995; 153(3 Pt 2):976-80.
13. Shapiro AM, Bain VG, Sigalet DL, et al. Rapid resolution of chylous ascites after liver transplantation using somatostatin analog and total parenteral nutrition. *Transplantation* 1996; 61:1410.
14. Combe J, Buniet JM, Douge C, et al. Chylothorax and chylous ascites following surgery of an inflammatory aortic aneurysm. Case report with review of the literature. *J Mal Vasc* 1992; 17:151-156.



Correspondence

Galanakis Joanny, MD

Department of Urology, San Bassiano Hospital
Bassano del Grappa (VI), Italy

Antonio Celia, MD

Department of Urology, San Bassiano Hospital
Bassano del Grappa (VI), Italy

Guglielmo Zeccolini, MD

Department of Urology, San Bassiano Hospital
Bassano del Grappa (VI), Italy

Dario Del Biondo, MD

Department of Urology, San Bassiano Hospital
Bassano del Grappa (VI), Italy

Guglielmo Breda, MD

Department of Urology, San Bassiano Hospital
Bassano del Grappa (VI), Italy

Kidney hibernoma: Case report and literature review.

Alessandro Delsignore, Stefania Ranzoni, Matteo Arancio, Carlo Marchetti,
Giuseppe Landi, Alessandro Mina, Maurizio Marcato, Carlo Martinengo

S.C. Urologia Asl NO - Presidio Ospedaliero di Borgomanero (NO), Italy

Summary

Objectives: Hibernomas are rare benign tumours originating from the brown adipose tissue. They occur generally in adults with a peak incidence in the third decade and with a slightly predominance in women. They are benign tumor that does not recur with complete excision. CT and RM images should not be misdiagnosed with atypical lipomas or well-differentiated liposarcoma. We report a case of incidental renal hibernoma discovered in a 51 years old women during open surgery for kidney pellic stone.

Case report: A 51-year-old woman presenting with recurrent left flank pain was diagnosed with left kidney stone. Abdomen ultrasound and i.v. pyelography showed pyelic stone of 2 cm without other pathologies of the urinary tract. Patient underwent left percutaneous lithotripsy complicated by severe bleeding. We converted into open surgery and incidentally we observed a brown, well-defined, encapsulated, and mobile mass of 1 cm that resulted to adhere to kidney capsule. We removed this lesion respecting surgical borders.

Intraoperative histological examination revealed cells with eosinophil cytoplasm and no evidence of mitosis or cellular atypia. Definitive histological examination show a well-circumscribed, encapsulated tumor, with large cells with central nuclei and multivacuolated granular cytoplasm. A rich vascular network was present absence of mitosis or atypia was confirmed. Histological diagnosis presumed hibernoma.

Conclusion: Our case report results one of the few cases of renal localisation of hibernoma that however need a surgical treatment.

KEY WORDS: Hibernoma; Brown adipose tissue; Surgical treatment.

Submitted 8 January 2010; Accepted 30 March 2010

INTRODUCTION

Hibernoma is a uncommon, benign soft tissue tumor, originating from fetal brown adipose tissue. It was first described in 1906 by Merkel as "pseudolipomas"; in 1914 Gery derived the name hibernoma because of a histological similarity to brown fat in animal hibernating. They occur in adult between the age of 30 and 50 years and they are more common in females (1).

A hibernoma usually manifests as a slowly growing, painless, soft-tissue mass.

The most common location is the subcutaneous tissue of the back, and particularly the interscapular area but it is usually found also in sites where brown fat is less common.

Diagnosis of hibernoma is based on histological examination. Since it is difficult to differentiate preoperatively between hibernoma and other soft-tissue tumors, such

as lipoma or liposarcoma, total surgical excision is the treatment of choice. Hibernoma is considered a benign tumor, and there have been no reports of malignant transformation.

We report a case of incidental renal hibernoma discovered in a 51 years old women during open surgery for kidney stone.

CASE REPORT

A 51-year-old woman presented with recurrent left flank pain. Ultrasound abdomen examination and Intravenous Urography (IVP) showed a left pellic stone of 2 cm without other pathologies or malformation of the urinary tract. No left flank lesion was palpated.

There was no significant past medical or surgical history.

In according to EAU guidelines left percutaneous lithitripsy was performed but was complicated by severe bleeding. We decided for an open approach and we found incidentally a brown, well-defined, encapsulated, and mobile masses of 1 cm that resulted to adhere to kidney capsule. We removed this lesion respecting surgical margins. The intraoperative histological examination revealed a compact, encapsulated specimen and cell with eosinophil cytoplasm; there was no evidence of mitosis or cellular atypia. Definitive histological examination showed a well-circumscribed, encapsulated tumor, large cells with central nuclei and multivacuolated granular cytoplasm. A rich vascular network was observed; absence of mitosis or atypia was conformed. Histological diagnosis presumed hibernomas. Post operative was complication-free and the patient was discharged from hospital on the fifth post-operative day. Two years later she remain free of symptoms with no sign of recurrence.

DISCUSSION

Two types of adipose tissue exist: white adipose and brown adipose. Brown adipose tissue was first described by *Wilsh* in 1670 (2). This highly specialized form of adipose tissue was first described in hibernating animals, but has also been reported in over 50 animal species, including non-hibernating animals such as rats, rabbits, monkeys, as well as man.

Although the exact function of brown fat is uncertain, it is believed to be important in nonshivering thermogenesis in hibernating animals and in the newborn. In humans, brown fat markedly decreases after 8 weeks of life, although small quantities remain in all age groups accounting for only 1% of total fatty tissue in adults (3).

When brown fat is overdeveloped and associated with hypervascularity and arteriovenous shunting at microscopic and imaging studies, this is typical for hibernoma.

Hibernomas seem to form in the areas with remaining brown fat, such as the scapular region, neck, axilla, chest wall, mediastinum, perirenal areas, thigh, buttock, popliteal fossa, scalp, breast, periureteric region, and scrotum (4, 5).

In literature few intrathoracic cases have been reported, and even fewer involving pleural locations; it is more frequently found in mediastinum and pericardium (6, 7).

Congregado et al. report the first case of pleural hibernoma treated with videothoroscopic surgery in a 53-years-old male patient (8).

They are soft, well-defined, encapsulated, and mobile masses. Their color varies from tan to red brown, depending on the amount of intracellular lipid. The diameter usually ranges from 5 to 10 cm, but they may reach up to 20 cm. They grow slowly and usually present with painless enlargement. Symptoms related to the compression of adjacent structures rarely develop. Histological examination reveals a well-circumscribed, encapsulated, lobu-

lated and homogeneous tumor, with a rich vascular network.

Microscopically, the tumor displays a lobular arrangement of rounded or polygonal cells classifiable in three types: (a) large, multivacuolated cells with eosinophilic granular cytoplasm; (b) small, rounded cells with granular cytoplasm; and (c) large, univacuolated cells with peripheral nuclei, resembling mature adipocytes. There is no evidence of mitosis or cellular atypia. A rich capillary network is generally found. Electron microscopy discloses multivacuolated cells containing abundant, large, pleomorphic mitochondria, with clearly-visible cristae and dense matrix; Golgi apparatus and endoplasmic reticulum are rarely seen (Figures 1-2) (9).

Core needle biopsy has not been recommended in cases of suspected hibernoma due to the tumor's hypervascu-

Figure 1.
Histological examination of hibernoma.

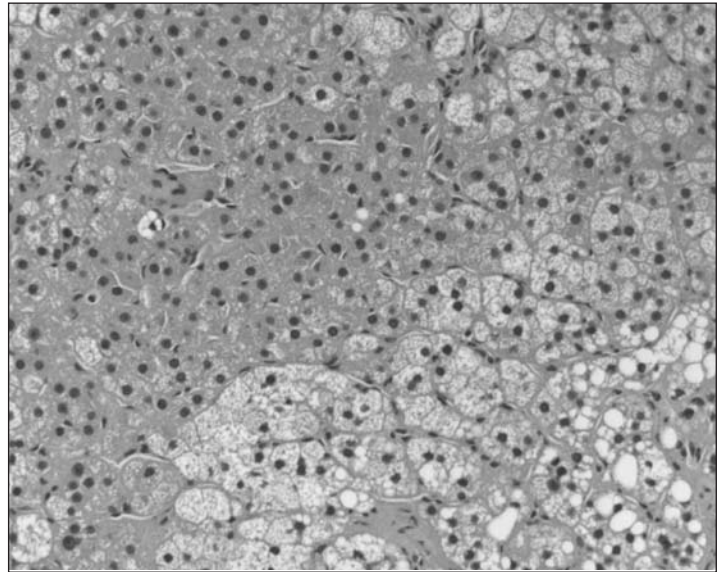
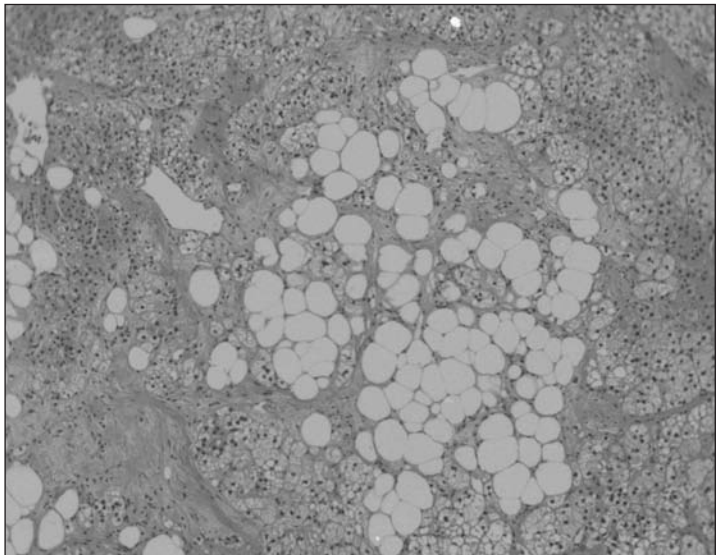


Figure 2.
Histological examination of hibernoma.



larity, and at least one case report documents excessive bleeding during a percutaneous biopsy of a hibernoma that resulted in termination of the procedure (10). Dursun *et al.* performed a core needle biopsy in all patients preoperatively, and no bleeding complication was noted in any patient (11).

Diagnosis of hibernoma is based on histological examination. No studies to date have reported an effective system for distinguishing between a hibernoma and other soft-tissue tumor with fatty content (in particular liposarcoma); therefore complete surgical excision is the only reliable approach.

Among the diagnostic procedures, CT, MR imaging can provide helpful information. Hibernomas are usually detected as heterogeneous masses with marked contrast enhancement.

The CT and MR imaging examinations show a well demarcated mass with signal intensity intermediate between subcutaneous fat and muscle and that enhances after contrast injection. Although they present as brown fat, the imaging characteristics on T1- and T2-weighted images demonstrate high signal intensity but slightly less than that of the subcutaneous fat.

Dursun (11) describe imaging findings of hibernoma on CT and MR in six patients: hibernomas are slightly hyperdense compared to the subcutaneous fat in CT examination and isointense or slightly hypointense compared to the subcutaneous fat in T1- and T2-weighted MR images, showing contrast enhancement and containing linear septations on CT or MR examination.

Radiographic, sonographic, angiographic, and scintigraphic appearances of this tumor have been described. Radiographs may show a mass with radiolucency consistent with a lipomatous neoplasm. No underlying osseous involvement is present (4). The sonographic appearance of hibernoma has been a uniformly hyperechoic mass. At angiography, these tumors have rich vascularity and occasional arteriovenous shunting (12).

CONCLUSION

Our case report results one of few cases of renal localisation of hibernoma that however need a surgical treatment.

REFERENCES

1. Rigor VU, Goldstone SE, Jones J, *et al.* Hibernoma: a case report and discussion of a rare tumor. *Cancer* 1986; 57:2297-311.
2. Rasmussen AT. The so-called hibernating gland. *J Morphol* 1923; 38:147-205.
3. Enzinger FW, Weiss SW. *Benign lipomatous tumors. Soft tissue tumors.* St Louis: Mosby 1995; 420-3.
4. Alvine G, Rosenthal H, Murphey M, *et al.* Hibernoma. *Skeletal Radiol* 1996; 25:493-6.
5. Kindblom LG. Intermuscular intramuscular lipomas and hibernomas, a clinical, roentgenologic, histologic and prognostic study of 46 cases. *Cancer* 1974; 33:754.
6. Ayarra Jarne J, García Díaz F, Jiménez Merchán R, *et al.* Hibernoma pleural. A propósito de una observación. *Neumosis* 1992; 4:33-6.

7. Udawadia ZF, Kumar N, Bhaduri AS. Mediastinal hibernoma. *Eur J Cardiothorac Surg* 1999; 15:533-5.

8. Congregado M., Jimenez-Merchan R., Arroyo A., *et al.*: Pleural hibernoma. Treatment by videothoracoscopic surgery. *Interactive Cardiovascular and Thoracic Surgery* 2004; 3:83-85.

9. Gaffney EF, Hergreaves HK, Semple E, *et al.* Hibernoma: distinctive light and electron microscopic features and relationship to brown adipose tissue. *Hum Pathol* 1983; 14:677-87.

10. Kallas KM, Vaughan L, Parviz H, *et al.* Hibernoma of the left axilla; a case report and review of MR imaging. *Skeletal Radiol* 2003; 32:290-4.

11. Durson M., Agayev A., Bakir B, *et al.* CT and MR characteristics of hibernoma: six cases. *Clinical Imaging* 2008; 32:42-47.

12. Baskurt E, Padgett DM, Matsumoto JA. Multiple hibernomas in a 1-month-old female infant. *AJNR Am J Neuroradiol* 2004; 25:1443-5.

Correspondence

Alessandro Delsignore, MD

S.C. Urologia Asl (NO)

Presidio Ospedaliero di Borgomanero - Ospedale SS Trinità

Viale Zoppis, 10 - Borgomanero, Italy

delsy@inwind.it

Stefania Ranzoni, MD

S.C. Urologia Asl (NO)

Presidio Ospedaliero di Borgomanero - Ospedale SS Trinità

Viale Zoppis, 10 - Borgomanero, Italy

Matteo Arancio, MD

S.C. Urologia Asl (NO)

Presidio Ospedaliero di Borgomanero - Ospedale SS Trinità

Viale Zoppis, 10 - Borgomanero, Italy

Carlo Marchetti, MD

S.C. Urologia Asl (NO)

Presidio Ospedaliero di Borgomanero - Ospedale SS Trinità

Viale Zoppis, 10 - Borgomanero, Italy

Giuseppe Landi, MD

S.C. Urologia Asl (NO)

Presidio Ospedaliero di Borgomanero - Ospedale SS Trinità

Viale Zoppis, 10 - Borgomanero, Italy

Alessandro Mina, MD

S.C. Urologia Asl (NO)

Presidio Ospedaliero di Borgomanero - Ospedale SS Trinità

Viale Zoppis, 10 - Borgomanero, Italy

Maurizio Marcato, MD

S.C. Urologia Asl (NO)

Presidio Ospedaliero di Borgomanero - Ospedale SS Trinità

Viale Zoppis, 10 - Borgomanero, Italy

Carlo Martinengo, MD

S.C. Urologia Asl (NO)

Presidio Ospedaliero di Borgomanero - Ospedale SS Trinità

Viale Zoppis, 10 - Borgomanero, Italy

Primary obstructive megaureter in adults: Management strategy in a young woman.

Andrea Solinas, Antoncarlo Pau, Mohammed Ayyoub, Mauro Frongia

Department of Renal Pathology, Unit of Urology, San Michele Hospital, Cagliari, Italy

Summary

Objective: Primary obstructive megaureter is an uncommon disease in adults. We describe a case in a thirty years old woman affected by monolateral megaureter complicated by ureteric calculi.

Material and method: The clinical presentation, renal function, radiologic data, complications and treatment were studied.

Results: The patient, with a history of recurrent right flank pain in the last ten years, had a right primary obstructive megaureter radiologically revealed complicated by ureteric calculi. Omolateral kidney result malrotated. Extensive ureteral tailoring with an extravesical ureteral reimplantation was performed. The calculi were removed at the time of ureteroneocystostomy.

Conclusion: Adult and adolescent primary obstructive megaureter is a congenital abnormality that do not regress. Complications such as stone formation and altered function of the affected kidney are common and when associated to recurrent urinary tract infections require surgical intervention. Conservative management probably has a role only in the uncomplicated primary megaureter patients with normal creatinine clearance and who have possibility of a regular life-long follow-up.

KEY WORDS: Megaureter; Megaureter treatment; Ureter reimplantation.

Submitted 29 January 2010; Accepted 15 May 2010

INTRODUCTION

Primary obstructive megaureter is characterized by a congenital obstruction at the lower end of the ureter just before it enters the bladder, leading to gross dilatation of the ureter especially in its distal one third. The condition was first described in 1923 by *Caulk* (1) and is due to an aperistaltic juxtavesical segment of 3 to 4 cm long that is unable to propagate urine at acceptable rates of flow. It is an uncommon disease in adults while is a common cause of lower ureteric obstruction in children and most may be detected in utero by antenatal ultrasonography. The diagnostic criteria are (a) dilated ureter as seen on intravenous urography, retrograde or antegrade pyelogram, ultrasonography or magnetic resonance urography; (b) lower end of ureter ending in a smooth taper; (c) absence of vesicoureteric reflux; (d) absence of infravesical obstruction; and (e) absence of organic obstruction at the lower end of the ureter as confirmed by cystoscopy and ureteral catheterization (2-3). The management in children is conservative, more than 50% of the megaureters regress with the growth of the child, presumably due to maturation of the vesicoureteric junction (4-5). Recurrent infection, significant deterioration of renal function or pain is an indication for surgery. The disease

in adults has a variable course and prognosis. The condition usually presents in the third or fourth decades of life. Men are more commonly affected than women (2). Unilateral disease is more common and is usually on the left side. The disease can present with flank pain, recurrent urinary tract infection, hematuria, and urolithiasis. Complications such as stone formation and deranged function of the affected kidney are common and almost all require surgical intervention. To report a case of 30-year-old girl affected by monolateral megaureter with ureteral calculi that required ureteral resection and reimplantation with tailoring.

CASE REPORT

A 30 years old woman complained a history of recurrent right flank pain in the last ten years in absence of infection, fever or other urological symptoms. Admitted in our hospital was examined with a plain X-ray of the abdomen, ultrasonography, urine analysis and culture, blood urea, serum creatinine, creatinine clearance and at conventional intravenous urography (Figures 1-2) was found to have a dilated lower third of the right ureter

ending in a narrow tapering segment complicated by ureteric calculi. Omolateral kidney result ptotic and mal-rotated, contralateral was normal. Obstruction was confirmed by a Tc^{99m}-DTPA scan performed with diuresis with the gamma camera moved to the level of vesicoureteric junction with perurethral catheter in place to drain the bladder. A ureteroneocystostomy with excision and tailoring of the lower end of the adynamic segment of the ureter with a extravesical approach was performed. Extravesical reimplantation involved mobilization of the distal ureter and dismemberment at the ureterovesical junction. Ureteric calculi was removed at the time of ureteric reimplantation. Indwelling ureteral stent was maintained for 4 weeks. The patient received broad spectrum antibiotics before and after the procedure until the stent and drains were removed. Patient was followed with urine culture, ultrasonography, and renal scan, first at 3 months from the date of surgery and then every 6 months during the next 2 years (Figure 3). Voiding cystourethrography was done at 6 months to rule out reflux. The follow-up was always satisfactory, no complication was encountered and now the patient is examined annually.

DISCUSSION

Primary obstructive megaureter in the adult most commonly present in the third and fourth decades of life (6) with reduced function or complications such as secondary calculi, recurrent infection or reduced function. Men are more commonly affected than women (3). In numerous studies are described histologic and ultrastructural anomalies that alter the ureteral function, disorientation of muscle, muscular hypoplasia, muscular hypertrophy and mural fibrosis are the most important (7). Electron microscopic studies demonstrated excess of collagen deposition increased matrix evidence with altered cell-to-cell junction and disrupts myoelectrical propagation and peristalsis (8-9). Ureteric profilometry shows irregular wave patterns so called "ureteroarrhythmias". The degree of ureteral dilatation depends on the amount of urine that is forced to coalescence proximally because of incomplete passage with obviously implications for the renal parenchyma (10). Allen proposed that the obstructive segment represent the crossing point of the umbilical vessel during intrauterine life, which should interfere with the

Figure 1.
Intravenous urography showing right megaureter with secondary calculi.

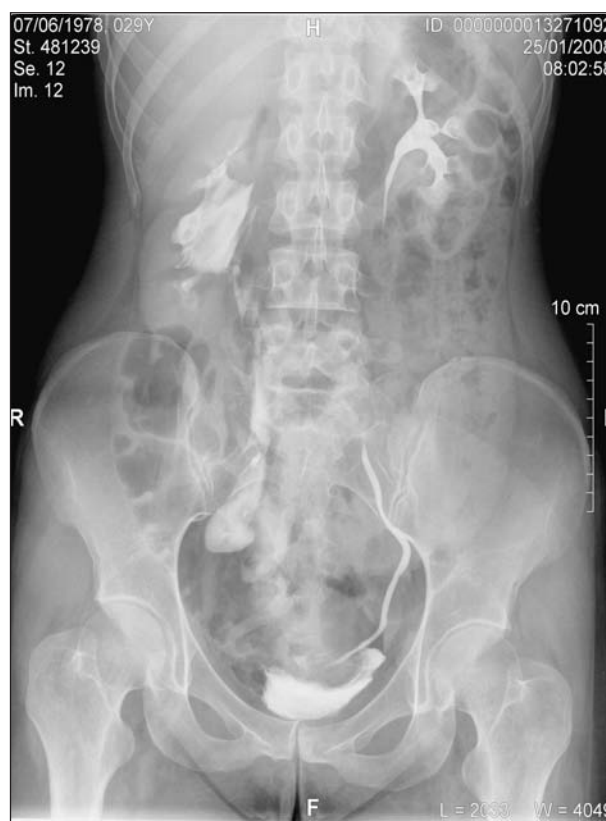

Figure 2.
Intravenous urography showing evidence the ureteral calculi.

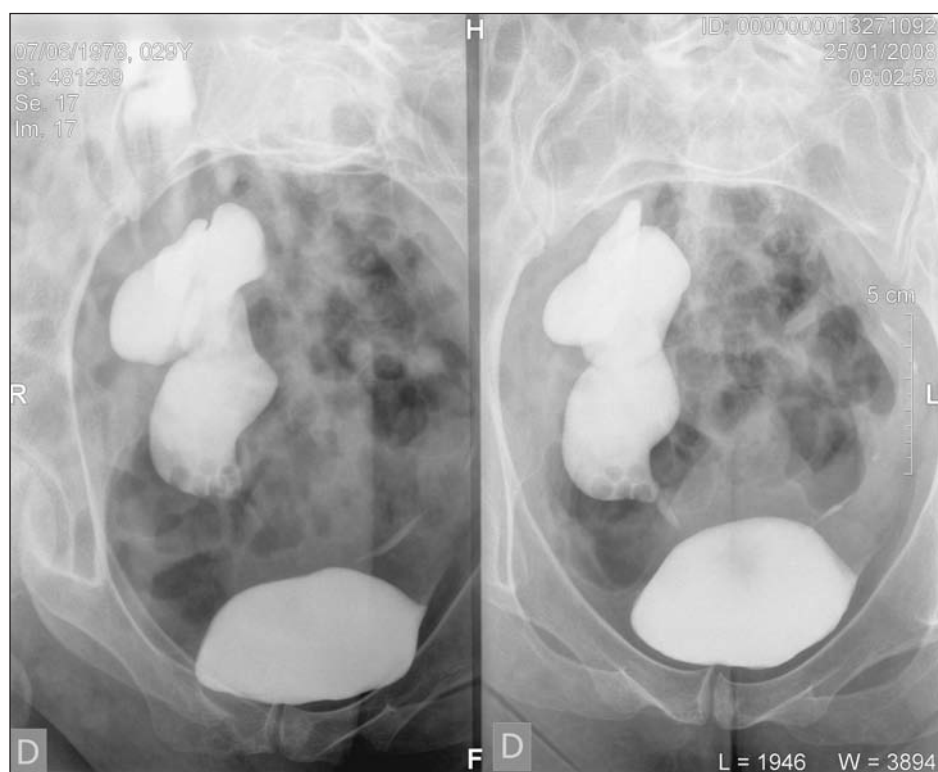
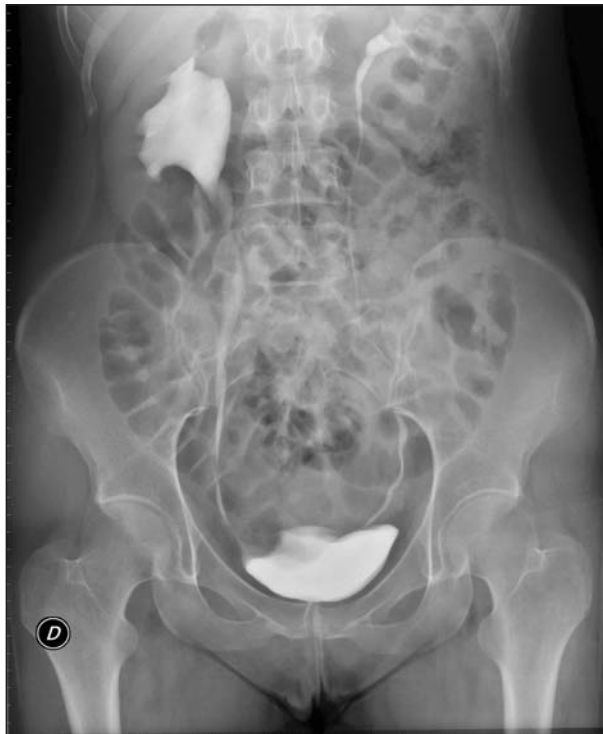

Figure 3.
Intravenous urography performed 3 months
after surgery show the excellent channelling of the ureter
and a malrotated omolateral kidney.



process of muscularization. All agree that the distal ureter is pathologic so it is to be excised with the reimplantation into the bladder with antireflux technique. The clinical presentation of primary obstructive megaureter are various and needs recognition as a separate entity in adults and adolescents because different is the treatment approach and the outcome. The majority of cases do not tend to require surgery particularly when they are discovered in utero by antenatal ultrasonography. The approach to asymptomatic cases is also initial non-operative management. Antibiotic chemoprophylaxis is prescribed and voiding dysfunction is addressed if present. Followup radiographic imaging is individualized according to the initial evaluation. Indications for operative treatment in an older child after close followup include worsening hydronephrosis along with deterioration in renal function and/or a prolonged radiotracer washout pattern in the involved kidney (11). Additional factors include the presence of symptoms, urinary tract infection and/or a tense flank mass on physical examination. The condition in adults is not innocuous as is often believed. Patients with megaureter, if left untreated, may develop secondary urolithiasis and end-stage renal disease (2). Surgical intervention seems ineffective once the patient has developed chronic renal failure. The proportion of symptomatic patients and stone disease is much higher as reported in published studies (2). Many authors recommended surgical correction in most adults, usually in the form of ureteric reimplantation to salvage renal function and prevent future complications at an early stage of diagnosis (12). Conservative management probably has a role only

in the uncomplicated primary megaureter patients with normal creatinine clearance and who have possibility of a regular lifelong follow-up.

REFERENCES

1. Caulk JR. Megaloureter: the importance of the ureterovesical valve. *J Urol* 1923; 9:315-19.
2. Hemal AK, Ansari MS, Doddamani D, et al. Symptomatic and complicated adult and adolescent primary obstructive megaureter-indications for surgery: analysis, outcome, and follow-up. *Urol* 2003; 61:703-7.
3. Dorairajan LN, Hemal AK, Gupta NP, et al. Primary obstructive megaureter in adults: need for an aggressive management strategy. *Int Urol Nephrol* 1999; 31:633-41.
4. Tokunaka S, Koyanagi T, Tsuji I, et al. Histopathology of the non-refluxing megaloureter: a clue to its pathogenesis. *J Urol* 1982; 127:238-44.
5. Oliveira EA, Diniz JS, Rabelo EA, et al. Primary megaureter detected by prenatal ultrasonography: conservative management and prolonged follow-up. *Int Urol Nephrol* 2000; 32:13-18.
6. Pfister RC, Hendren WH. Primary megaureter in children and adults: Clinical and pathophysiologic features of 150 ureters. *Urol* 1978; 12:160-76.
7. Tanagho EA, Miller ER. Functional considerations of urethral sphincteric dynamic. *J Urol* 1973; 109:273-8.
8. Hanna MK, Jeffs RD, Stugges JM, et al. Ureteral structure and ultrastructure, part II, Congenital ureteropelvic junction obstruction and primary obstructive megaureter. *J Urol* 1976; 116:725-30.
9. Pagano P, Passerini G. Primary obstructed megaureter. *Br J Urol* 1977; 49:469-75.
10. Pace G, Simoncini G, Silvestri V, et al. Bilateral megaureter: management strategy in a ninety years old woman. *Arch Ital Urol Androl* 2007; 79:158-60.
11. Pitts WR Jr, Muecke EC. Congenital megaloureter: a review of 80 patients. *J Urol* 1974; 111:468-73.
12. DeFoor W, Minevich E, Reddy P, et al. Results of tapered ureteral reimplantation for primary megaureter: extravesical versus intravesical approach. *J Urol* 2004; 172:1640-3.

Correspondence

Andrea Solinas, MD
Azienda Ospedaliera G. Brotzu
Ospedale San Michele, S.C. di Urologia
Pzzale A. Ricchi 1 - 09134 Cagliari, Italy
sol.andrea@tiscali.it

Antoncarlo Pau, MD
S.C. Urologia, Azienda Ospedaliera G. Brotzu
Pzzale A. Ricchi 1 - 09134 Cagliari, Italy

Mohammed Ayyoub, MD
S.C. Urologia, Azienda Ospedaliera G. Brotzu
Pzzale A. Ricchi 1 - 09134 Cagliari, Italy

Mauro Frongia, MD
S.C. Urologia, Azienda Ospedaliera G. Brotzu
Pzzale A. Ricchi 1 - 09134 Cagliari, Italy